DEC 20 1946

VOLUME LVI NOVEMBER, 1946 NUMBER 11

MEDICAL LIBRARY

THE LARYNGOSCOPE

FOUNDED IN 1896
BY
MAX A. GOLDSTEIN, M. D.

PUBLISHED BY
THE LARYNGOSCOPE
640 SOUTH KINGSHIGHWAY ST. LOUIS (10), MO., U. S. A.

NOTICE TO CONTRIBUTORS

THE LARYNGOSCOPE reserves the right of exclusive publication of all articles submitted. This does not preclude their publication in Transactions of the various Societies.

Manuscripts should be typewritten, double spaced, on one side of paper only and with sufficient margins to allow for corrections.

References should be complete: author's surname, initials, title of article, journal, volume, page, month, year.

Six illustrations will be furnished for each article without cost to author. Authors will please limit illustrations to six or assume the expense of additional illustrations.

Proofs will be submitted to authors for corrections. If these are not returned, articles will be published as corrected in this office.

Reprints will be furnished at the following prices:

	250 Copies	500 Copies	1000 Copies	2000 Copies
WITHOUT COVER				
Four Pages	$ 7.25	$ 8.75	$11.75	$17.50
Eight Pages	15.00	19.00	25.50	38.00
Twelve Pages	22.50	28.50	40.50	64.50
Sixteen Pages	29.00	35.50	47.50	70.00
Twenty Pages	35.00	43.00	59.00	88.00
Twenty-four Pages	42.50	51.50	69.50	104.50
Thirty-two Pages	55.00	66.00	88.00	129.00
WITH COVER				
Four Pages	$13.25	$17.00	$24.50	$39.00
Eight Pages	21.00	27.25	38.25	59.50
Twelve Pages	28.50	36.75	53.25	86.00
Sixteen Pages	35.00	43.75	60.25	91.50
Twenty Pages	41.00	51.25	71.75	109.50
Twenty-four Pages	48.50	59.75	82.25	126.00
Thirty-two Pages	61.00	74.25	110.75	150.50

Express charges to be paid by consignee.

THE
LARYNGOSCOPE.

VOL. LVI NOVEMBER, 1946. No. 11

MY MILESTONES.

HARRIS P. MOSHER, M.D.,
Marblehead, Mass.

PART I.

INTRODUCTION.

An Emeritus Professor, and I am one, is often classified among the "unburied dead." I don't like the classification, hence this paper. It was planned at first to be given on the Instruction Program of the American Academy of Ophthalmology and Otolaryngology. It turned out to be far too long, and only a part of it will be read. Dr. Lierle told me politely, a little over a year ago, that I had overstayed my market in writing so constantly on the esophagus and on osteomyelitis of the frontal bone, and suggested that I take new topics. I have followed his suggestion. The title of the paper "My Milestones" simply means that I have chosen subjects that have meant much to me, and in connection with some of which I have done a little work on my own account. The paper is, therefore, both personal and impersonal.

The following are the subjects discussed in this Instruction Hour:

Surgery of the frontal sinus.
Brain abscess.
Thymic deaths.

Editor's Note: This ms. received in Laryngoscope Office and accepted for publication, Sept. 14, 1946.

Lung abscess.
Open tracheotomy.
Surgical precepts.

The first two — frontal sinus surgery and brain abscess — are the main subjects.

In the complete paper 21 subjects are discussed.

THE NASO-FRONTAL DUCT.

My first personal milestone in laryngology was the approach to the naso-frontal duct by the agger nasi cell. Please don't ask me for dates, as I am getting a bit sensitive on this subject. When I began the practice of otolaryngology it was the custom to drain the frontal sinus by way of the naso-frontal duct hoping to avoid an external operation. Curved rasps were used to enlarge the duct at the expense of its anterior boundary, the ascending process of the superior maxilla. The rasp was guided to the sinus by feel or passed along a probe. This was before we had the help of X-ray. One surgeon passed a gold cannula into the sinus and had the patient wear it for weeks or months. This resulted in gold in the surgeon's pocket, but it did not cure the patient, because when the tube was withdrawn the connective tissue stirred up by the rasping rapidly narrowed or closed the enlarged drainage channel. In no other surgical location in otolaryngology does connective tissue take its revenge more quickly and thoroughly than about the naso-frontal duct.

The naso-frontal duct resents trauma whether it is applied from below, that is, from the nose, or from above, that is, from within the frontal sinus. Hilding and Walsh have done some illuminating experiments on the sinus end of the duct, the point of their work being that trauma at or near the sinus opening of the naso-frontal duct tends to close it.

Years ago I coined the aphorism, "Respect the virginity of the naso-frontal duct or take the consequences." This wisecrack is still true, and the remark seems still to be quoted. Enlarging the naso-frontal duct should not be done in acute infection of the frontal sinus, although it was recently

attempted by an otolaryngologist in the neighborhood of Boston, and resulted in a near tragedy. The procedure is of value as a palliative one in chronic infection if the floor of the sinus is deep antero-posteriorly. If the basal relationship between the sinus and the nose is narrow, it is only of temporary value.

ACUTE INFECTION OF THE FRONTAL SINUS.

In acute infection of the frontal sinus which does not respond to nasal shrinking and perhaps to judicious suction in the region of the middle meatus the only intranasal surgery indicated is infraction of the middle turbinate, or the removal of the anterior end of the middle turbinate and the opening of an agger nasi cell if one is present. No attempt should be made to catheterize the naso-frontal duct and to wash out the sinus. In the last few years these procedures are being supplanted by a better one, namely, making a small drill opening in the front wall of the sinus, or better, in the floor at McEwen's point, and washing out the sinus for a few days to a week with a solution of penicillin. Dr. Schall reports that he has repeatedly had acute frontal sinusitis clear up by using this procedure, even if there was edema over and above the sinus well onto the skin of the forehead. Dr. MacMillan, the roentgenologist at the Infirmary, reported one of Dr. Schall's cases where a small patch of osteomyelitis resolved under this treatment, and in discussing this case with me, he stated that by using the procedure of draining the sinus with a small external opening and irrigating with penicillin, the stormy cases of acute frontal sinusitis which used to go on to osteomyelitis have become much fewer. If this happening continues it will mark a great advance in the treatment of acute infection of the frontal sinus.

This procedure has been in the literature for some years. As far as I can recall (I am quoting from memory) Shea was the first to use it. J. Mackenzie Brown has long employed it, and has reported it. I did not take to it at first; however, on learning of its successes naturally I now favor it. An external opening of the sinus is much simpler than trying to

enter the sinus from the nose by way of the naso-frontal duct. It does not upset the mucous membrane of the duct and lead to its closure. It is absolutely safe, whereas the intranasal approach to the sinus is not.

THE KILLIAN RADICAL SINUS OPERATION.

When I began to do radical frontal sinus operations the Killian technique was in full swing. It called for the removal of the whole front wall of the sinus with the exception of a supra-orbital bridge, the complete removal of the floor, and the exenteration of the anterior ethmoidal cells. The skin over the front face of the sinus and the soft tissue beneath it were pressed back against the posterior wall of the sinus in an attempt to obliterate it. Fat from the orbit was supposed to well up and to help in accomplishing this.

I soon gave up the true Killian operation. I did what I called a modified Killian. I took away only enough of the front wall of the sinus to remove all septa and all mucous membrane. Around the opening in the front wall a rim of bone was left which kept the sinus from obliterating. The idea was to get a permanent scar tissue cavity and the hope was that the opening into the nose would remain patent.

The trouble which I found with the full Killian operation was that it would not always obliterate, that unobliterated pockets would form, especially at the outer angle of the sinus, which would later necessitate a revision of the operation. Other drawbacks were that occasionally the bridge of bone above the inner canthus of the eye would necrose and sequestrate, and in very large sinuses the Killian operation gave a prohibitive deformity. In the early days we had no satisfactory method of correcting the deformity.

I have never been satisfied with any radical frontal sinus operation which I have tried. During my term at the Infirmary the frontal sinus operations by various members of the staff, including my own, were the least satisfactory of all the sinus operations.

What happened to my cases which had recurrences was

that they would go along all right for a number of years — four or five perhaps — and then after an infectious cold or a ride in an automobile with the wind shield down, the scar would puff up and headache would return. Examination of the nose would show pus and polypi in the region of the anterior part of the middle meatus. A little curetting, however, would re-establish the opening into the sinus and the symptoms would subside for another period of years. Finally I would lose sight of the case. This is what happened in 20 per cent of my radical frontals, and this is why I have never been satisfied with the operation.

THE LYNCH RADICAL FRONTAL SINUS OPERATION.

Lynch revived and improved the Ritter frontal sinus operation which removed only the floor of the sinus. His improvement consisted in a thorough removal of the posterior ethmoidal cells as well as the anterior. He made a thorough removal of the posterior cells possible by getting better vision by taking off nearly the whole of the os planum. The globe of the eye was retracted strongly downward and outward to give more operating room. He paid little attention to the pulley of the superior oblique and in one instance at least, had permanent double vision on the operated side.

The Ritter-Lynch is the popular radical frontal sinus operation today. It was heralded as a sure cure, but I happen to know that it can fail. My objection to it is that it is harder to remove septa in the sinus, especially where they occur at the outer angle, and it is more difficult to be certain of the condition of the posterior wall of the sinus.

I still reserve the right to make an adequate surgical opening in the anterior wall of the sinus any time I think it is indicated.

In radical frontal sinus operations many attempts have been made to transplant mucous membrane in the region of the naso-frontal duct. Skin grafts have been tried and even the turning in of full thickness skin flaps. To my knowledge none of these procedures has proven successful enough for

general adoption. Some operators feel that the wearing of a tube of tantalum or of one of the new plastics offers hope of keeping the opening from the sinus into the nose patent. A rubber catheter drains while it is in place but mucous membrane does not reproduce around it. It is an ostrich procedure, because when the catheter is withdrawn the old problem of connective tissue overgrowth has to be faced.

The failure of the radical sinus operation — and any type of operation can fail, is due in the great majority of cases to an overgrowth of connective tissue in the region of the nasofrontal duct, or to an infected and unopened fronto-ethmoidal cell which is in series with the posterior wall of the frontal sinus. A sinus X-ray plate taken in the Water's position will show such a cell, and the presence or absence of this cell should be known to the surgeon before he attempts any type of radical operation on the frontal sinus.

Frontal sinus surgery in my hands has been bitterly disappointing. Temporary favorable results have been common. Permanently favorable results I never could guarantee. I do not consider that any type of operation can be called a permanent success until you get beyond three or four, perhaps five years.

At the last meeting of the American Laryngological Association, Dr. Francis L. Weille of the Massachusetts Eye and Ear Infirmary Staff read a paper entitled, "The Problem of Secondary Frontal Sinus Surgery." He reported 276 Infirmary cases which had been operated a second time by various members of the staff. Of these one-third had more than one external operation. One patient had nine. Many of the first operations, however, were done outside our hospital, and the cases were referred to the Infirmary as a last resort, so the story is not quite so bad for the Infirmary as the statistics at first sound.

Among the secondary operations in the Infirmary series, so-called obliterating operations figured largely. Most of these were obliterating only in name. They consisted in taking off the anterior wall or part of it, removing the floor and

packing the sinus until it obliterated, which in many, if not most cases, did not happen. The obliterating operation, I feel, has a chance of success only if the removal of the anterior and posterior walls of the sinus is carried out, and this has to be done regardless of the resulting deformity. We have learned that a tantalum implant will correct this, and with chemotherapy to help out, you do not have to wait a year before correcting the deformity. Dr. Weille cited one case where it took five years with multiple operations before the deformity was corrected. This should never be necessary again.

Unless the newer methods of keeping a sufficient opening from the floor of the sinus into the nose are successful — I refer to Goodale's method of suspending a strip of tantalum foil in the enlarged naso-frontal duct, or using a tantalum tube as employed by Weille, or an acrylic mould with a skin graft as advocated by Hoople and others — unless these procedures, one or all, prove to be successful, the operation of choice for a secondary operation is an obliterating operation worthy of the name, one which is something more than wishful thinking; however, the success to date of the use of tantalum foil or the tantalum tube in the naso-frontal duct is distinctly encouraging.

Walsh's experimental work on the frontal sinus is significant. I have referred to this before. He did not enlarge the naso-frontal duct and left the sinus opening of the duct alone. When the duct was not interfered with it stayed open.

When the Killian radical frontal sinus operation or the Ritter-Lynch operations fail, it is my feeling that it is better to turn at once to the obliterating operation. I feel that the obliterating operation should be done as the primary operation where there is extensive necrosis of the posterior wall of the frontal sinus or where an exploratory opening of the posterior wall reveals an extradural abscess.

It is possible, of course, that the future will show that

penicillin will make the obliterating operation unnecessary in these cases.

A small frontal sinus, that is, one that is hardly more than a superior ethmoidal cell, can be easily obliterated by removing the whole of the anterior wall and repeatedly packing the cavity of the sinus until it fills up with granulations.

The common method of attempting to obliterate a normal or a large frontal sinus after removing the anterior wall and its floor seldom succeeds. Generally an unfilled pocket, often at the outer angle, persists, and prevents obliteration.

THE OBLITERATING FRONTAL SINUS OPERATION.

The following is the description of an obliteration operation on the frontal sinus which I believe has the best chance of succeeding.

Since I am no longer doing surgery, the type of operation I am about to describe might be called arm chair surgery as I have not done it. It is based on the favorable results in obtaining obliteration of the frontal sinuses in the radical operation for osteomyelitis without removal of the floor of the sinus. Perhaps some adventurous colleague might like to try it. The procedure which I have in mind is as follows: Remove thoroughly both the anterior and the posterior walls of the frontal sinus, leaving a good supra orbital rim. Do not remove the floor. As you want the naso-frontal duct to close curette it lightly from the sinus end. If the patient's condition permits exenterate the anterior ethmoidal cells; if not, do this at a secondary operation. If the posterior ethmoidal cells are markedly diseased exenterate these along with the anterior cells at the primary operation after the technique of Lynch. Press the skin and the soft tissues beneath it back against the dura and hold them there by the surgical dressing. Insert a small wick for drainage. If the skin and the soft tissues do not adhere to the dura and so obliterate the main part of the sinus the inner portion of the skin incisions should be opened and the cavity of the sinus packed until it granulates up from the bottom.

When it is a question of obliterating the frontal sinus there is one drawback to leaving the floor of the sinus intact. If the sinus has a deep orbital prolongation, or if it has a fronto-ethmoidal cell in series with it, both of these, in chronic infection, have to be opened, and this is best accomplished by removing at least part of the floor of the sinus.

Time alone will tell whether our surgical dream of many years of keeping the nasofrontal duct continuously open can now be accomplished by the use of tantalum foil, a tantalum tube or an acrylic mould and make the majority of primary operations for chronic infection of the frontal sinus successful; but when these procedures fail and a secondary operation becomes necessary I feel that an obliterating operation after the technique just described offers the best chance of success.

LOCALIZED OSTEOMYELITIS OF THE ANTERIOR OR POSTERIOR WALL OF THE FRONTAL SINUS.

It is my firm belief based on the histological examination of bone specimens, that when the anterior wall of the frontal sinus is infected, the posterior wall also is infected.

In acute infection of the frontal sinus, if there is a subperiosteal abscess, the sinus should be drained by a small opening in the anterior wall or in the floor of the sinus, but when necrosis of the front wall occurs a sufficient opening should be made in the posterior wall to find out the condition of the dura and to rule out an extradural abscess. This procedure is analagous to uncovering the lateral sinus to rule out a perisinus abscess or thrombosis of the lateral sinus.

It has long been the custom to remove necrotic portions of the posterior wall. I am advocating an exploratory opening of the posterior wall whenever the anterior wall is necrotic, and the posterior wall appears normal, because there is a 50 per cent chance that the dura is infected and accompanied by an extradural abscess.

FULMINATING OR SPREADING OSTEOMYELITIS OF THE FRONTAL BONE.

It took me a long time to sense the fundamental importance of infectious thrombophlebitis in infection of bone. The late Dr. Harry P. Cahill was the first one to bring it to my notice. It is the basic pathological condition in osteomyelitis of the frontal bone. It is the same in bone infection in the mastoid process.

For many years we had indifferent success in our surgical treatment of osteomyelitis of the frontal bone. Most of the cases which came to the Massachusetts Eye and Ear Infirmary followed swimming and were of the fulminating type. By turns I was radical, for me at least, and then conservative in my operations. It was always rear guard action. Furstenberg then came out with a brilliant series of successful cases after radical surgery. Following his lead I supervised seven cases treated radically, but done by other surgeons of the Infirmary Staff. These cases gave better results than we ever had before. The histological examination of the large bone specimens from the cases gave information which upheld the opinion that radical operation, in fulminating cases at least, gave the best results. I kept at this histological work for seven years.

Summarized, the results of these studies were: The diploic veins of the frontal bone are practically always present. They are absent in only 3 per cent of skulls. They connect with the veins of the mucous membrane of the frontal sinus which in infected membrane are found to be very numerous, and in proportion to the thickness of the frontal bone, very large, often measuring a third of the thickness of the frontal bone. The diploic veins are the transportation system of the infection.

EDEMA.

Further it was found that the characteristic pitting edema of osteomyelitis is due to enlargement and infection of the subperiosteal veins and to edema of the periosteum itself.

The routine examination of large sections of osteomyelitic frontal bone proved that the edema of the skin was a rough guide to the limit of the infection in the diploic veins, and the edema, therefore, was used as the upper limit of the section of bone to be removed.

In fulminating cases of osteomyelitis unless chemotherapy causes a recession of the edema in 48 hours, I still feel that the bone removal should extend to the limit of the edema. In acute infection of the frontal sinus it is not uncommon to have edema over the front face of the sinus and a short distance up the forehead. It is the reaction of the skin to nearby infection. The edema is more or less localized, does not spread and does not pit. The patient is not septic. Drainage of the sinus causes this superficial edema to disappear quickly. When the edema spreads rapidly, is brawny and pits, it means that there is marked thrombophlebitis in the diploic veins and the edema coincides with the limit of the infection in the veins.

All edema over the frontal sinus or over the frontal bone is not frank osteomyelitis but it is *potential* osteomyelitis and the surgeon should heed the warning which it gives.

Two more important points were brought out by the histological examination of large bone specimens during the seven years of this investigation: *1.* The X-ray does not show bone necrosis for seven to ten days after the beginning of the spreading edema; the surgeon loses most valuable time if he waits for this to appear, — not only loses valuable time but in many instances sacrifices his patient.

2. Whenever the X-ray shows a spot of necrosis in the frontal bone or the surgeon uncovers one at operation, the bone around it is dangerously infected for an inch and half to two inches. I am speaking of the fulminating cases. The least that the surgeon can do and have a clear conscience is to remove this infected area to the amount just indicated.

CHEMOTHERAPY.

In discussing osteomyelitis of the frontal bone, the burning question is how many cases can chemotherapy alone cure. It has cured some and will cure more, especially cases where the

infection is of a lower grade than in the fulminating cases. Its drawbacks are that it has led to tragic watchful waiting and that it has no effect on walled off pus. Walled off pus is what leads to the four fatal complications of osteomyelitis, namely extra- and subdural abscess, brain abscess, and meningitis. In some instances chemotherapy obscures and confuses the surgical picture.

The feeling is growing that chemotherapy, especially the use of penicillin, will in many instances convert a fulminating case of osteomyelitis into a subacute type with the formation of a sequestrum. If this opinion proves to be correct this action of chemotherapy will be a marked advance in the treatment of osteomyelitis. Until the advent of chemotherapy watchful waiting has been the great cause of disaster in the treatment of osteomyelitis.

The medical men in the Army have had the supreme chance to evaluate the sulfa drugs and penicillin. One observation recently made about penicillin by Putney deserves careful consideration. He said that although penicillin will promptly sterilize free pus, the infection will return unless penicillin is given continuously for a considerable period. Putney recently reported three such recurrences.

Chemotherapy has led to some modifications of the radical operation. Time alone will tell what type of case it will cure, and how much it will modify the radical operation in fulminating cases. One modification which is now justifiable is the following. In cases where the X-ray shows that only one sinus is involved, it has been our habit to operate on both sinuses since it was found that in spite of a negative X-ray on one side, in fulminating cases of osteomyelitis both sinuses were infected. I feel it is justifiable with chemotherapy helping us, to operate only the frankly involved side. An obliterating operation should be done on this side. The less involved side according to X-ray should have a small drainage opening and irrigations of penicillin. Chemotherapy should be tried in all cases. If it quickly controls the spreading edema, watchful waiting in spite of its tragic record is justifiable.

When osteomyelitis of the frontal bone is due to trauma it usually involves but one spot in the bone. It is a localized affair and tends to form a sequestrum. Chemotherapy might possibly clear up beginning osteomyelitis due to trauma or bring about early sequestration and minimize the amount of bone removal necessary at operation.

In osteomyelitis I feel very strongly that enough bone should be removed in all cases to discover and uncover all the extradural abscesses which may be present. I have seen as many as three widely scattered over the frontal dura. The great objection to a large removal of the frontal bone has always been the resulting deformity during the long convalescence before cosmetic repair could be undertaken. With sulfa drugs or penicillin this period can be shortened and with the modern metallic inlays the deformity can be entirely eliminated; therefore, there is every surgical reason for a generous removal of bone until the surgeon is satisfied that no extradural abscess has been left uncovered.

I will close this chapter on the frontal sinus with four rather minor points. In doing the Killian operation or the radical operation for osteomyelitis of the frontal bone where an incision is made parallel to the eyebrow, it formerly was the custom to make it through the center of the eyebrow. Dr. Kazanjian advises, from his experience in plastic repair, that the horizontal incision should be made just above the eyebrow, not through it, as it is difficult to bring the halves of the eyebrow together nicely.

A few times in opening a mucocele of the frontal sinus I found it filled with a currant-jelly-like clot, and attributed this to hemorrhage into the mucocele. Just where in the mucous membrane the blood came from, I could not tell. Later in a specimen of early infection of the ethmoid I found that the only pathological change was hemorrhage between the base of the mucous membrane and its attachment to the perichondrium of the bone. I took this to be one of the very early changes due to infection. In a case of osteomyelitis of the frontal bone complicating acute infection of the frontal

sinus there were both profuse submucosal hemorrhage and massive hemorrhage into the cavity of the sinus.

In my experience if the median portion between the two frontal sinuses is perforated during an operation on one of the sinuses, in most cases the normal sinus becomes infected.

In the Lynch operation the floor of the sinus is removed by the orbital approach. In the Killian operation we were taught to remove it by standing above and behind the patient's head, and working downward from within the sinus. When one visualizes the floor of the frontal sinus as the upward outward extension of the os planum and follows the os planum upward and outward, he can be sure of getting out the whole of the floor of the sinus. This seems a simple point, but it was years before it dawned upon me. The floor of the fronto-ethmoidal cell also is a projection upward and outward of the os planum. Following upward the os planum is the surest way to discover such a cell and to successfully open it. This is the only safe way to open up an orbital prolongation of the sinus, especially if it is a deep one.

To be continued in the December, 1946, issue of

THE LARYNGOSCOPE.

AMERICAN BOARD OF OTOLARYNGOLOGY.

The American Board of Otolaryngology will conduct the following examinations in 1947:

April 16 to 19 in St. Louis, Mo., at the Coronado Hotel.

October 7 to 11 in Chicago, Ill., at the Palmer House.

Address inquiries to Dean M. Lierle, M.D., Secretary-Treasurer, Iowa City, Iowa.

PERIPHERAL FACIAL PARALYSIS. SOME ASPECTS OF ITS PATHOLOGY.*

TERENCE CAWTHORNE, M.D.,
London, England.

INTRODUCTION.

The small amount of pathological material available to illustrate the causes and nature of the various lesions responsible for peripheral facial palsy is in no small measure due to the essentially harmless nature of the condition; moreover, in those cases in which the injury, disease or growth responsible for the paralysis has involved neighboring and more vital structures with fatal results, the florid picture presented by the fatal condition has usually overshadowed the facial palsy, with the result that advantage has not been taken of the opportunity to collect material for detailed examination of the lesion responsible for the facial paralysis.

Thus most of our knowledge of the effect upon the nerve trunk of lesions causing peripheral facial paralysis has been gained from direct exposure and inspection of the nerve trunk at the site of the lesion, and it may be noted that this procedure has only met with general approval during little more than the past decade.

Alt (1908) was the first to advocate direct exposure of the nerve trunk at the site of the lesion, and Ney (1922) made a contribution to the understanding of the nature of the condition that foreshadowed much of the work that was to follow. Mackenzie (1922), Bunnell (1927), Smith (1931) and Martin (1931) all favored direct exposure of the nerve.

It was, however, the paper presented at the summer meeting of the American Otological Society, Inc., in 1931, by the late Sir Charles Ballance and the late Dr. Arthur Duel (Bal-

*Read by invitation at the Seventy-eighth Annual Meeting of the American Otological Society, Inc., Chicago, Ill., June 1 1946.

Editor's Note: This ms. received in Laryngoscope Office and accepted for publication, July 23, 1946.

lance and Duel, 1932) that led to the general acceptance of the principle that in cases of severe peripheral facial paralysis consideration should be given to exposure of the nerve trunk at the supposed site of the lesion. This paper aroused worldwide interest and since then many workers have reported their experiences, including Tickle (1938), Morris (1938), Cawthorne (1938), E. P. Fowler, Jr. (1939), Collier (1940) and Kettel (1943).

This principle of examining the affected part of the nerve trunk is an essential step towards the appreciation of the pathology of peripheral facial paralysis, and the present paper is based upon personal observations made on a series of 93 cases of peripheral facial paralysis in which the nerve trunk was exposed. In the course of describing what was seen, both with the naked eye and through the Leitz binocular dissecting microscope giving 10 diameters of magnification, the value of which has already been noted in these cases (Cawthorne, 1941), suggestions will be made as to the possible cause of the paralysis in certain instances.

INDICATIONS FOR EXPOSURE OF THE NERVE.

Clearly it is not desirable to expose the nerve in more than a proportion of cases of facial paralysis, for many recover spontaneously.

It is for this very reason that in the past it has been the general custom in all cases of facial paralysis — no matter what the cause — to wait for the nerve to recover spontaneously even though the nature of the lesion causing the paralysis made a spontaneous recovery improbable if not impossible. Present opinion favors exploration of the nerve trunk in cases of continued paralysis where the lesion is thought to be surgically accessible.

Generally speaking, paralysis of all the muscles supplied by the facial nerve, combined with an inability of the nerve to conduct a faradic current (q.v.) applied through the skin, but with a response to galvanic stimulation of the musculature, is an indication of a lesion of the nerve trunk suffi-

ciently severe to have caused degeneration in the nerve fibres distal to the lesion.

These electrical reactions can be very helpful and I have always made a point of seeing for myself the reactions being carried out. Allowances have to be made for certain variations caused by testing through the skin, and in some instances, particularly in children, an anesthetic is necessary before the test can adequately be carried out. The reaction of degeneration may appear as early as 72 hours after a complete severance of the nerve, but my colleagues in the physical medicine department at King's College Hospital, Dr. Clayton and Dr. Cooksey, assure me that a faradic response may persist in a severed nerve for as long as 14 days.

I have not yet had any experience with the electric myograph.

It is important for the surgeon to have some idea of the site of the lesion in order that he may decide whether it is surgically accessible. As a rule it is accepted that the trunk can be exposed anywhere from its division in the face to the geniculate ganglion. Tickle has, however, described a case in which the stump of the divided nerve at the level of the dura was seen and a graft applied, and Tremble and Penfield (1936) describe an exposure of a tumor of the great superficial petrosal nerve. In the present series there were two cases in which the nerve had been affected at or near the internal auditory meatus.

Apart from the paralyzed facial musculature, the most, and I think the only consistently reliable clue to the site of the lesion, is the effect upon the sense of taste in the anterior two-thirds of the tongue on the same side. A detailed account of the solutions in general use for testing taste is given in a monograph, "The Chemical Senses," by Moncrieff (1944).

I have never been able to satisfy myself that a lesion proximal to where the nerve to the stapedius is given off ever interferes with hearing, although some reporters state that involvement of the stapedial nerve results in intolerance of loud low sounds.

The third possible clue to the level of the lesion is at the geniculate ganglion from where secretomotor fibres to the lacrimal gland are carried by the great superficial petrosal nerve via Meckel's ganglion. A lesion of the facial nerve trunk proximal to the geniculate ganglion is said to interfere with the secretion of tears in response to conjunctival stimulation. The test is not an easy one to evaluate and I feel that the possibility of lacrimal secretion being continued, even when the great superficial petrosal nerve is cut out, cannot be excluded; therefore, although these three functions are tested in all cases of peripheral facial paralysis that are seen, it has been found that taste is the only one upon which reliance can be placed.

CAUSES AND NATURE OF LESION.

The description by Kettel (1943) of the various causes of facial paralysis in a large series of cases deserves careful consideration, and in many instances the findings that will be described approximate to his.

In the 93 cases in which the nerve was exposed, the causes have been set out in the following table and an account of what was found will be given under the heading of each cause.

CAUSES OF PERIPHERAL FACIAL PARALYSIS IN WHICH THE NERVE WAS EXPOSED AT OR NEAR THE SITE OF THE LESION RESPONSIBLE FOR THE PARALYSIS.

1. Operative injury		32
Radical mastoid	14	
Cortical mastoid	11	
Labyrinth operation	4	
Foreign body removal	3	
2. Bell's palsy		26
3. Chronic suppurative otitis media		15
4. War injury		11
Air raid (retained foreign body, 2)	6	
Battle (retained foreign body, 1)	5	
5. Skull fracture		4
6. New growth		3
Neurofibroma, VIth nerve	2	
Neurofibroma, VIIth nerve	1	
7. Accident		2
(Retained foreign body, 1)		

1. Operative Injury (32).

In all but one of the 32 cases of operative injury, the nerve had been damaged in the fallopian canal proximal to where the chorda tympani leaves the nerve trunk. In the remaining case the nerve had been cut shortly after its exit from the stylomastoid foramen in the course of an attempt to remove a foreign body from the external auditory meatus by a post-auricular incision.

Site Within the Fallopian Canal. In describing the different portions of the fallopian canal the descriptive terms used by Horelacque (1926) will be used, the nerve being divided into labyrinthine, tympanic and vertical segments, with a bend or pyramidal segment uniting the tympanic and vertical portions.

a. Tympanic Segment (10).

This was the site of injury in 10 operations, five being after radical mastoidectomies, three after operations on the labyrinth and two following attempts to remove foreign bodies.

b. Bend of Pyramidal Segment (14).

In the 14 cases in which the bend was the site of injury, six followed radical, seven cortical, and one a labyrinth operation.

c. Vertical Segment (7).

Of these seven cases, all above the level of the chorda tympani, three had followed radical, and four cortical mastoid operations.

Nature of Injury.

a. Total Division of Nerve and Sheath with Loss of Segment of Bony Fallopian Canal (8).

This was noted in eight cases, four being radical, two labyrinth, and two cortical operations. With this amount of destruction, landmarks were difficult to identify and the area

of the injury was usually a jumble of fibrous tissue. It was in this group of cases particularly that the increased magnification offered by the binocular dissecting microscope was of such help in identifying the nerve ends.

b. Total Division of Nerve with Preservation of Part of Sheath and Bony Canal (11).

Of these 11, five were radical, one labyrinth, and five cortical operations.

c. Partial Division of Nerve with Preservation of Part of Sheath and Bony Canal (7).

Of these seven, three were radical, one a labyrinth, and three cortical operations.

d. Damage of Nerve Without Solution of Continuity (6).

Of these six, two were radical, one a cortical operation, and three followed attempted foreign body removal. In five of the cases the nerve had been injured by crushing as the result of the bony wall of the fallopian canal being driven inwards. This could be clearly seen in two of the foreign body, and one of the radical cases in which the very thin, almost transparent bony wall of the fallopian canal in its tympanic segment could be seen to have been crushed like an indented eggshell.

Associated Injuries (9).

The external semicircular canal had been opened accidentally in seven cases, two radical and five cortical operations, and in every instance the injury to the nerve was at the bend and it seemed likely that both structures had been damaged by a single gouge cut.

In two cases an abnormally forward lateral sinus (q.v.) had been damaged.

Anatomical Variations.

In eight cases an abnormally forward lateral sinus had been uncovered at the first operation, but in only one of these

had the dura of the middle fossa been exposed. Mention has previously been made of the temptation to go too far forward and down when confronted with a forward lateral sinus (Cawthorne, 1938). The fact that in only one such case had the dura of the middle fossa been exposed recalls the teaching of Cheatle (1908), who never failed to impress upon his assistants the value of the dura as a guide to the mastoid antrum, and whenever in doubt as to one's whereabouts he always advised exposing the dura of the middle fossa and following it inwards until the antrum was reached.

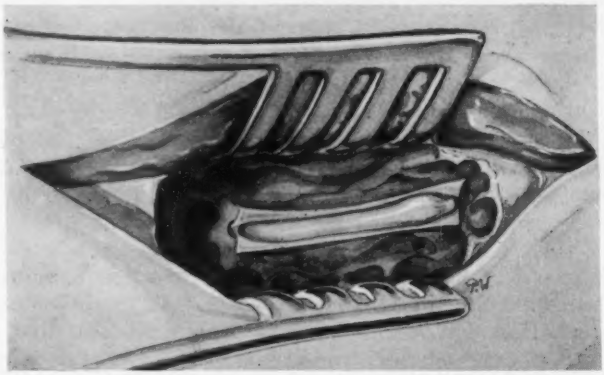

Fig. 1. This drawing was made from an operation for Bell's palsy and shows the vertical segment of the facial nerve as seen through the dissecting microscope. The swelling of the nerve trunk above, a constriction in the region of the stylomastoid foramen is clearly depicted.

2. Bell's Palsy (26).

In every case subjected to decompression of the vertical segment. there had not been any response to faradic stimulation after two weeks, and in all but four, taste on the anterior two-thirds of the tongue on the affected side has also disappeared. In the earlier cases in this group little attention was paid to the appearance of the nerve except to note some bulging of the nerve in the lower part of the fallopian canal after opening the sheath. In the last 14 cases, however, par-

ticular notice was taken of the appearance of the nerve in the region of the stylomastoid foramen. In 12 of these, it was found that the nerve trunk appeared to be unduly constricted at this level, the constriction being accentuated by swelling of the nerve immediately above it. At the site of the constriction there were noted several tiny hemorrhagic streaks running longitudinally. In cases of recent origin it was found that within a few minutes of incising the nerve sheath the constriction became less noticeable.

It will be appreciated that a certain narrowing at the stylomastoid foramen may be considered as being within anatomical limits, but the appearance just described is in excess of any normal alteration in caliber, and the billowing out of the nerve above the constriction after incision of the sheath is in my experience peculiar to this condition. In two cases in which the paralysis had been present for more than six months the nerve trunk in the neighborhood of the stylomastoid foramen was found to be shrunken, reddened and adherent to the sheath.

3. Chronic Suppurative Otitis Media (15).

A record of the cases of chronic suppurative otitis media is available only for the past six years — in the other cases the records extend over 11 years — so it is probable that the number of cases in this group seen in a comparable period exceeds 15. In nine cases the nerve sheath was found to be exposed in the posterior part of the tympanic segment or in the bend, and in five of these there was in addition an erosion of the bony external semicircular canal. In the remaining six cases no breach of the bony canal could be seen.

No records are available of the number of cases of facial paralysis seen in the course of an acute suppurative otitis media, but I do not recall ever having seen a case that did not recover spontaneously.

4. War Injury (11).

Some idea of the relative frequency of facial paralysis as a war injury may be gained from the experience at a large

war emergency hospital at Horton near Epsom during the latter half of 1940 where, out of 2,277 air raid and battle casualties admitted, six were found to have sustained injury to the facial nerve (Cawthorne, 1942).

Air Raid Casualties (6).

In all six, the nerve was damaged after its exit from the stylomastoid foramen by wounds in the region of the lower attachment of the pinna. In five of these, splinters of glass were thought to have been the cause of the damage, and in two, pieces of glass in direct contact with the nerve were discovered. The nerve trunk had only been actually divided in two cases; in the other four a swelling in the nerve trunk indicated the original site of the damage.

Battle Casualties (5).

In only two of the five battle casualties had the nerve been damaged in the face. In the other three it had been injured in the fallopian canal in the vertical segment, and in one the labyrinth had also been injured. In one of these, a small piece of oiled silk, probably part of an antigas visor, caused continued suppuration until it was removed.

5. *Skull Fracture* (4).

It has only been during the past two years that an exploration of the facial nerve trunk in the fallopian canal has been undertaken in cases of skull fracture complicated by facial paralysis. In the first two cases continued aural suppuration with loss of cochlear and vestibular function called for exploration, which in each instance revealed a severe fracture with fragmentation involving the inner tympanic wall and the facial nerve in its tympanic segment. In one of the remaining cases there had been a short bout of ear discharge, followed by deafness, facial paralysis and reduced but definitely not abolished responses to vestibular stimulation. Here the nerve was found to be involved in a fracture extending from the tegmen tympani downwards and forwards into the anterior part of the inner tympanic wall. In the fourth case following a skull fracture there was a complete facial paraly-

sis, partial deafness but no obvious diminution in vestibular activity. At operation it was found that at the bend and in the upper part of the vertical segment there had been a hemorrhage within the sheath of the nerve. In both these latter cases on otoscopy the normal appearance of the visible part of the ossicular chain was altered due to displacement downwards and forwards of the incus. Although the number of cases in which the possibility of a surgically accessible lesion of the nerve has been appreciated is small, it is felt that skull fractures in which facial paralysis is accompanied by signs of damage to the ear, particularly if the middle ear is affected, should be considered as possible instances of fracture involving the middle ear cleft and the facial nerve as it runs along its inner wall.

6. New Growth (3).

In two cases of neurofibroma of the VIIIth nerve in which the growth was limited to the temporal bone, facial weakness was the first sign. In each instance the tumor was removed via the temporal bone, but in neither was it possible to see the facial nerve in the neighborhood of the growth. In the third case, a neurofibroma was found in the lower part of the descending portion of the nerve in the fallopian canal. This case was first considered to be a case of Bell's palsy as there were no other signs to suggest the real cause. This rare condition has already been described by Pasture and Williams (1939).

7. Accident (2).

In one case a button hook had been introduced into the external auditory meatus with the object of removing wax and it had been driven into the middle ear, fracturing the fallopian canal in its tympanic segment just anterior to the foramen ovale. In the other case a motor car accident had resulted in severe lacerations around the pinna. At operation, some months after the accident, the nerve trunk was found to be damaged in the face and at the point of damage a piece of twig was found to be lying.

CONCLUSIONS.

The cases which have just been described are not intended accurately to indicate the relative frequency of the various causes of peripheral facial paralysis, but they do include all the cases seen during the past 12 years in which direct exposure of the nerve at the suspected site of the lesion was undertaken. Since 1938, I have been using the binocular dissecting microscope (x10) for these cases, and the value of the additional information and assistance afforded by working in a magnified field cannot be too strongly emphasized. It gives a very clear picture of the lesion, and in cases where the nerve has been divided it lessens the difficulty of finding the divided ends.

Finally, I would like to draw attention to the cases of skull fracture in which the nerve was found to be damaged in a surgically accessible part of the fallopian canal.

I should like to express my gratitude to my colleagues at King's College Hospital, the National Hospital for Nervous Diseases, Queen Square, Horton Emergency Hospital and elsewhere, for giving me the opportunity of seeing these cases; and to my assistants, particularly Mr. A. Wardale and Mr. J. P. Clayton, for their help in collecting the material for this paper.

REFERENCES.

ALT, F.: *Verhandl. d. deutsch Otol. Gesselsch*, 191, 1908.

BALLANCE, C. A., and DUEL, A. B.: The Operative Treatment of Facial Palsy. *Arch Otol. and Laryngol.*, 15:1, 1932.

BUNNELL, S.: Suture of Facial Nerve Within the Temporal Bone. *Surg., Gyn. and Obst.*, 45:7, 1927.

CAWTHORNE, T.: Discussion on Limitations of Operative Treatment for Facial Paralysis. *Proc. Royal Soc. Med.*, 34:582, 1941.

CAWTHORNE, T.: Nerve Grafting in Facial Paralysis. *Trans. Med. Soc. London*, 60:171, 1938.

CAWTHORNE, T.: Traumatic Facial Paralysis. *Med. Press and Circular*, p. 260, 1942.

CHEATLE, A. H.: Surgical Anatomy of the Temporal Bone. Churchill, London, 1908.

COLLIER, J.: Facial Paralysis and Its Operative Treatment. *Lancet*, p. 91, July, 1940.

FOWLER, E. P., JR.: The Management and Treatment of Afflictions of the Facial Nerve Within the Fallopian Canal. *Acta Otol.*, 27:615, 1939.

HOVELACQUE, A.: Anatomie des nerfs craniens. Gaston Doin et Cie, Paris, 1926.

KETTEL, K.: Facial Palsy of Otitic Origin. *Arch. Otolaryngol.*, 37:303, 1943.

MACKENZIE, D.: La paralysie faciale. No. 5, Monographie O., R., L. internationale. A. Legrand, Paris, 1922.

MARTIN, R. C.: Intratemporal Suture of the Facial Nerve. *Arch. Otolaryngol.*, 13:259, 1931.

MONCRIEFF, R. W.: The Chemical Senses. Hill, London, 1944.

MORRIS, W. M.: Surgical Treatment of Bell's Palsy. *Lancet*, p. 429, 1938.

NEY, K. W.: Facial Paralysis and the Surgical Rupture of the Facial Nerve. THE LARYNGOSCOPE, 32:327, 1922.

PASTURE, P. N., and WILLIAMS, H. L.: Neurofibroma of the VIIth Nerve Involving the Mastoid. *Proc. Staff Meet. Mayo Clin.*, 14:524, 1939.

SMITH, J.: Decompression of the Facial Nerve for Postoperative Facial Palsy. *Ann. Otol., Rhinol. and Laryngol.*, 40:1179, 1931.

TICKLE, T. G.: The Surgical Treatment of Facial Paralysis. Art. in Loose-Leaf *Surgery of the Ear*. Kopetsky Nelson, New York, p. 365, 1938.

TREMBLE, G. E., and PENFIELD, W.: Operative Exposure of Facial Canal with Removal of a Tumor of the Greater Superficial Petrosal Nerve. *Arch. Otolaryngol.*, 23:573, 1936.

INTERNESHIPS ESTABLISHED AT IOWA STATE UNIVERSITY.

Through a cooperative arrangement between the State University of Iowa and the Iowa State School for the Deaf, two interneships have been established in the State School for the Deaf. Students holding these interneships spend one semester in the School for the Deaf and the other semester of the school year on the university campus where they serve as research assistants. During their interneships, the students work intensively in the teaching of speech to the deaf, lipreading, audiometry, personality adjustment procedures, and they also spend a large share of their time observing the regular classroom teaching in the school besides devoting a part of their time to research. During the semester which they spend on the university campus, their research assistantships are served in the Department of Otolaryngology where they assist with speech testing, audiometry, hearing aid fitting and research. The program involves four appointments each school year. Further information may be obtained from Dr. Wendell Johnson, Director of the Speech Clinic at the State University of Iowa.

FACIAL NERVE SURGERY IN THE EUROPEAN THEATER OF OPERATIONS.*

FRANK D. LATHROP, M.D.,
Boston, Mass.

Facial paralyses occurring as a result of battle wounds in the war of 1914-1918 were treated either by anastomotic operations between the distal stump of the facial nerve and the central end of an adjacent motor nerve, or by various plastic surgical procedures designed to minimize the asymmetry of the face. These methods of treatment left considerable room for improvement, and as early as 1922 Ney[6] recognized that "the only hope of restoring bilaterally coordinated emotional expression after a paralysis of the facial nerve lies in the restoration of the functional integrity of the nerve." In the same article he described a method by which primary suture of the divided ends of the facial nerve could be accomplished when the defect in the nerve was no greater than 1 cm. and, in the event of a greater loss of substance of the facial nerve, recommended using the sensory portion of the radial nerve as a graft. It was not until 1925, however, that the intratemporal repair of a traumatized facial nerve by primary suture was first accomplished by Bunnell.[2,3] Still later, Ney's recognition of the feasibility of grafting the facial nerve was verified by Bunnell, in 1930 and, in 1931, by Ballance and Duel when they restored the function of the facial nerve by the utilization of nerve grafts. Since then, the practicability of these methods of treating traumatic facial palsy has been proven by numerous surgeons.

One would think that these advances in facial nerve surgery would have permitted casualties exhibiting facial paralyses as a result of wounds received in the recent war to obtain treatment best adapted to correct the lesion of the facial

*Read at the Seventy-eighth Annual Meeting of the American Otological Society, Inc., Chicago, Ill., June 1, 1946.

Editor's Note: This ms. received in Laryngoscope Office and accepted for publication, July 23, 1946.

nerve. Unfortunately, this has not been true and the treatment of facial paralysis incurred by military personnel in this war has proved to be as haphazard as it undoubtedly was during the first World War.

From July, 1944, to July, 1945, approximately 150 cases of facial nerve paralysis of the peripheral type were encountered, the majority of which were the result of battle wounds. The remainder were either idiopathic or incurred secondary to accidents, non-battle wounds or mastoidectomy. It was impossible, due to the press of other professional duties, to operate in all those cases in which it was believed that exploration of the facial nerve was indicated; however, 45 of these patients who presented either partial or complete peripheral facial paralysis were operated upon during this period, and various corrective procedures employed as governed by the pathologic lesion of the facial nerve discovered at operation whenever possible. The data accumulated through study of the cases comprising this series have proven to be instructive with respect to the evaluation of the prognosis for spontaneous recovery from the palsy, the effect of traumatic agents upon the temporal bone and facial nerve, and the feasibility of the various surgical procedures designed to obtain relief from the facial paralysis. The operated cases in this series conclusively demonstrate that the anatomical restoration of the continuity of the facial nerve is possible in the majority of cases. Similar data have been collected by Maj. Gordon D. Hoople and Captain A. C. Johnson,[5] which in all probability will be reported at a future date.

Traumatic lesions of the facial nerve constitute a small proportion of all wounds resulting from modern warfare and are of little importance as a casualty figure. Foerster[4] reported 120 instances of involvement of the VIIth cranial nerve in a series of 3,907 injuries to nerves incurred by German army personnel during the war of 1914-1918, while statistics of the medical department of the United States Army revealed that the facial nerve was paralyzed in only 72 instances among 153,537 battle casualties who survived the initial effects of their wounds during the years 1917 and

1918. It is possible, however, that such figures are not truly representative of the frequency of traumatic facial paralysis among battle casualties because of failure to note an existing palsy associated with a wound in which considerable tissue destruction has occurred and which is of greater immediate importance to the casualty.

Facial paralyses in military personnel are either idiopathic or traumatic in origin. The lesions presented by facial nerves traumatized as a result of modern warfare are frequently more extensive and complex than those encountered in civilian practice and vary with the etiology, location and extent of the wound. Fractures of the facial bones, mastoid process or jaws are almost always present in such battle casualties, and concurrent paralyses of the IInd, Vth, VIth, VIIIth, IXth, Xth, XIth and XIIth cranial nerves are common.

Those paralyses occurring as a result of the blast of nearby explosives apparently have their origin in an intraneural pathologic change produced by the pressure waves associated with such explosions, as in no case was a fracture demonstrable by Roentgenologic examination, and spontaneous recovery occurred. Deafness and rupture of the tympanic membrane, as further evidence of the blast effect, were associated with the facial paralysis in each case.

When high or low velocity missiles produce wounds that result in facial palsy, the physiologic interruption of the nerve is the effect of concussion, compression, contusion or destruction of a portion of the facial nerve. Such wounds are almost always associated with fractures of the temporal, facial or mandibular bones, although on occasion minute fragments may either enter the external auditory canal or pass between the stylomastoid foramen and the mastoid tip to contuse or section the facial nerve. These missiles produce wounds of either the penetrating or perforating type and commonly result in extensive fracturing or disruption of the mastoid process. High velocity missiles, because of their relatively flat trajectory, have a tendency to injure the vertical or cervical segments of the facial nerve in the vicinity of the stylomastoid foramen. Low velocity missiles, on the other hand,

are more likely to involve the intratympanic and vertical course of the nerve in the neighborhood of the horizontal semicircular canal and it is in wounds of this origin that associated paralyses of the cranial nerves traversing the pharyngomaxillary space are most commonly seen.

The most significant feature of the wounds in this category which resulted in interruption of the facial nerve was the severity of the injury sustained by the nerve. Exploration, on several occasions, demonstrated the facial nerve to be so badly traumatized as to require the insertion of a nerve graft from the region of the geniculate ganglion to within a few millimeters of the pes anserinus to restore its continuity. Losses which involved a portion of the mastoid and cervical segments were common. Infrequent, but offering an extremely poor prognosis for repair, were those wounds which involved the pes anserinus as well as its immediate branches. Furthermore, it was not uncommon to discover at operation that the facial nerve had been injured at more than one point in its course. Displacement of the severed ends of the facial nerve by the wounding agent and destruction of the usual anatomical landmarks related to the path of the facial nerve presented difficulties in effecting a repair of the nerve in a number of instances.

Severance of the facial nerve as a result of knife or bayonet wounds of the face or neck occurred infrequently in this series. Such wounds usually produce partial paralysis of the face through division of one or more of the principal branches of the facial nerve in its facial distribution. It was found relatively easy to effect a repair of such injuries to the facial nerve by primary suture because of the lack of displacement or wide destruction of the nerve and the ease with which mobilization of the severed ends could be accomplished. The most striking feature of such wounds was the failure to locate and approximate the severed ends of the nerve at the time the original closure of the wound was performed.

The location and extent of the wound producing the facial paralysis are of importance in evaluating the trauma incurred by the facial nerve and in arriving at a decision to explore

the nerve. Gutter wounds of the temporal bone superior to the external auditory canal and those grazing the mastoid process apparently produced a concussional type of palsy as spontaneous recovery from the facial paralysis occurred when the middle ear was not directly involved. Wounds involving the mastoid process at the level of the external auditory canal or below usually produced facial palsy as a result of compression, contusion or dissolution of a portion of the nerve. Penetrating and perforating wounds with the point of entrance or emergence situated between the lobule and tragus of the external ear frequently severely injured the pes anserinus and made repair difficult. Branches of the facial nerve in its distribution to the facial musculature often were contused or severed in the deep lacerations produced by the explosive action upon the soft tissues of missiles of modern warfare and resulted in partial paralysis of the face.

Extensive wounds frequently present multiple areas of damage to the facial nerve, the presence or absence of which can be ascertained only by careful exploration of the nerve in the path of the wound. For example, the facial nerve has been found at operation to present a large defect in its vertical course and division of the superior branches in the face, while, in another, a large neuroma at the stylomastoid foramen, partial destruction of the cervical trunk and avulsion of the pes anserinus and its immediate branches were noted.

Considerable emphasis has been placed upon the assessment of electrical reactions, Roentgenologic examination and tests for taste and tearing in determining the nature and location of the damage to the facial nerve in civilian cases of facial palsy. Such examinations, other than the response to faradic current, have been of relatively little significance in the majority of cases comprising this series. Radiographic examination of the temporal bone and taste testing have been of little value in localizing the trauma incurred by the facial nerve. Tests for the presence or absence of taste in the ipsilateral anterior two-thirds of the tongue have been unreliable because of the severe concussion sustained by the nerve. Roentgenologic studies were difficult to evaluate either be-

cause they were inadequate or because of inability to determine when a fracture was producing the injury to the facial nerve. On the other hand, testing for the presence or absence of increased lacrimation on nasal irritation proved to be of value in determining whether or not the injury sustained by the nerve was located distal or proximal to the geniculate ganglion. The response of the facial musculature upon percutaneous electrical stimulation of the facial nerve with the faradic current was the greatest single factor in determining whether to explore the facial nerve and in arriving at a prognosis for spontaneous recovery from the facial paralysis.

The treatment of facial paralysis of the peripheral type secondary to wounds received in modern warfare, in which the available evidence indicates that injury of the facial nerve distal to the internal auditory meatus has occurred, is surgical. Facial nerve surgery of this nature is justly within the domain of the otologic surgeon, for only the well-trained otologist fulfills its prerequisites — an exact knowledge of the anatomy of the facial nerve and the ability to accomplish the adequate treatment of the pathologic processes within the middle or inner ear with which such palsies are most commonly associated.

The grotesquerie of facial expression resulting from this palsy has stimulated many constructive efforts for the relief or cure of such paralyses. As a result, there now are several operations for dealing with facial paralysis of the peripheral type which give satisfactory results when the proper surgical procedure is instituted that is best adapted to deal with the existing pathologic process.

Operations, such as decompression, primary suture and nerve grafting of the facial nerve, restore the physiologic function of this nerve to a variable degree in the majority of cases and permit the greatest possible return of emotional response to the paralyzed face. It is this latter aspect of the treatment of facial paralysis that is of greater importance in facial nerve surgery. Although anastomotic operations between the facial nerve and the spinal accessory or hypo-

glossal nerve frequently result in satisfactory voluntary movements of the muscles of the face, the reaction to emotional stimulation usually is poor. In addition, such anastomoses commonly produce associated movements of the face on swallowing or moving the shoulders which are of annoyance to the patient. Undoubtedly, the degree of symmetrical response of the face to emotional stimulation following these operations is largely dependent upon the ability of the patient to depress the play of emotion on the sound side of the face, while at the same time overaccentuating the opposite facial movements. It is only logical to assume that this can best be accomplished in those cases in which the normal pathway for the transmission of such impulses from the cerebral cortex is intact.

It is not my purpose to review the techniques involved in the performance of these operative procedures, for this information can best be obtained by reference to the original papers by Bunnell[2] and Ballance and Duel.[1] I should like to point out at this time, however, that the method of rerouting the facial nerve as described by Bunnell has not received the attention it warrants. Gaps in the facial nerve as great as 23 mm. may be repaired by primary suture if this procedure is employed in suitable cases in which the existing pathologic condition permits the performance of a radical mastoidectomy. It would seem advisable to obtain end-to-end suture of the facial nerve whenever possible, for, by the elimination of a second neural junction, one more obstacle to the downgrowth of axons from the central stump of the facial nerve into the peripheral segment is removed (see Fig. 1).

Decompression, end-to-end suture, nerve grafting, hypoglossofacial anastomosis and fascia lata slings have been utilized in the operated cases in this series as the pathologic condition present indicated. The decision as to which of these operative procedures was to be employed in any given instance was dependent upon the location and the nature of the damage sustained by the facial nerve as determined at exploration. The facial nerve was decompressed in 10, sutured in 12, grafted in 15 and anastomosed with the hypoglossal nerve

in one of the 45 operated cases in this series. It was impossible to obtain a pathway for neurotization of the facial musculature in the remaining seven patients. These included two patients in whom the pes anserinus and its immediate branches were destroyed and repair of the facial nerve thus unable to be effected, although the facial deformity was satisfactorily corrected in one by fascial slings, a patient who developed a psychosis and had to be returned to the Zone of the Interior before nerve grafting could be completed, and

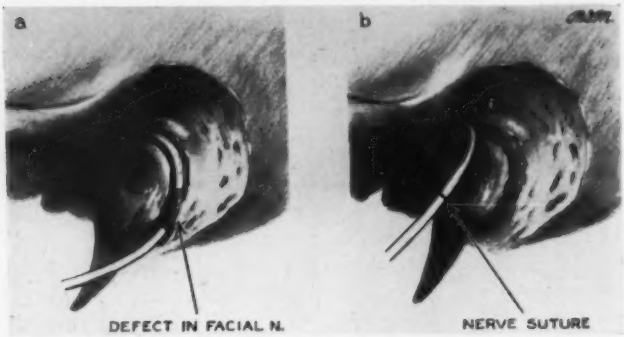

Fig. 1. Rerouting facial nerve. **a**, Facial nerve uncovered in facial canal. **b**, End-to-end suture accomplished. (Reprinted from Surgical Clinics of North America, June, 1946.)

four patients in whom the severed ends of one of the branches of the facial nerve in its facial distribution could not be located during the course of operation primarily intended for excision of a scar of the face.

The function of the facial nerve was recovered in all but two patients in whom decompression of the nerve alone sufficed to correct the injury to the nerve. Death occurred from meningitis in one of these two patients while he was being returned to the Zone of the Interior and before sufficient time had elapsed to permit recovery from the facial paralysis; no progress report has been obtained from the other. The injury to the nerve in all of these patients had occurred either in the

fallopian canal, neck or face. The degree of voluntary and emotional recovery obtained in several patients of this group would indicate that when the facial nerve is severely traumatized, though grossly intact, it would be better to excise the area of damage and effect a repair by primary suture or nerve graft.

The integrity of the facial nerve has been restored in so far as possible in 11 of the 12 cases in which end-to-end suture of the trunk of the facial nerve or its branches was accomplished. It has not been possible to obtain a progress report

Fig. 2. Recovery following end-to-end suture of cervical trunk of right facial nerve, overcoming loss of 12 mm. **a**, Emotional response; **b**, voluntary contraction of both sides of face.

from one patient. The defects in the facial nerve in each of these cases ranged from 5 to 23 mm. and was overcome by adequate mobilization of the nerve so that primary suture, without undue tension of the trunk of the nerve, could be obtained on six occasions and of one or more of the branches in its facial distribution in the remainder. In general, the voluntary and emotional play of the facial musculature in these patients have been quite satisfactory following return of function (see Fig. 2). In those cases, however, which required decompression as well as primary suture to effect a repair or in which it was impossible to locate and suture all of the branches of the facial nerve, poorer results were obtained.

Particular attention has been directed to follow-up reports in those cases in which nerve grafting was employed because of the skepticism prevalent among neurosurgeons with respect to this method of repairing nerve injuries. Follow-up reports from qualified neurosurgeons stipulate that voluntary movement and emotional expression have been restored to the paralyzed face in 10 of 15 patients in whom the anatomical continuity of the facial nerve was accomplished in this manner. Grafts obtained from the anterior femoral cutaneous nerves, ranging from 15 mm. to 50 mm. in length, were used

Fig. 3. Result following 45 mm. nerve graft of right facial nerve, extending from the vicinity of the geniculate ganglion to within a few millimeters of the pes anserinus. **a**, Repose; **b**, voluntary contraction of both sides of face.

to close the defect in the facial nerve, and on several occasions the course of the graft ran vertically across the middle ear to effect a repair extending from the geniculate ganglion to the pes anserinus (see Fig. 3).

It is necessary to consider further the five cases in which nerve grafting apparently failed to effect a repair. In three of these patients sufficient time has not elapsed between operation and the last progress report to permit a final determination to be made as to whether the function of the facial nerve will be restored. Two of these patients report, how-

ever, that their facial asymmetry is less and that the "numb feeling" of their face has decreased, which would tend to indicate that return of movement to the paralyzed face is imminent, since these are the first signs of progress to be observed during recovery from facial paralyses. Sufficient time has passed since grafting was accomplished in one instance to admit failure, while the nerve graft in the remaining case was accidentally removed while the patient was receiving postoperative care by another surgeon.

Anastomosis of the distal stump of the facial nerve with the central end of either the spinal accessory or hypoglossal nerve should be reserved for those cases of facial paralysis in which it is impossible to effect a repair by primary suture or nerve grafting. Hypoglossofacial anastomosis has been necessary on one occasion in this series. The return of voluntary movements to the paralyzed side of the face is satisfactory, whereas the emotional recovery is poor.

It should not be expected that the physiologic function of the facial nerve will be returned to normal by the employment of any method of treating facial paralysis. The degree of function spontaneously recovered in a Bell's palsy of one or two months' duration is less than that which existed prior to the occurrence of the paralysis in spite of the fact that the optimal conditions exist for the re-establishment of the neurogenic pathway, since interruption of the anatomical continuity of the facial nerve has not occurred. Consequently, if only a single neural junction is present to act as an obstacle to the passage of new nerve fibres from the central to the peripheral segment of the divided facial nerve, the resulting degree of recovery is far from normal. Many of the downward growing nerve fibres fail to pass the neural junction and those that do pass it do not necessarily re-establish the formerly existing neurogenic pathways. As a result, mass movements always occur and inadequate neurotization and atrophy of the facial musculature frequently do not permit complete return of function. The latter is particularly true of the muscles of the superior half of the face. When evaluating the results obtained in the operative cases in this series,

if the following are taken into consideration—*1.* the severe concussion the facial nerve has sustained, *2.* on several occasions more than one lesion was presented by the traumatized nerve, and *3.* it was not always possible to restore the anatomical continuity completely — it should be obvious that the degree of functional recovery obtained in these cases will be less than that observed following similar methods of treating facial nerve paralyses occurring in civilian practice. The extent to which the function of the facial nerve has been recovered and the fact that the anatomical restoration of the continuity of the facial nerve has been possible in the majority of instances, however, would seem to demonstrate the feasibility of such operative procedures as decompression, end-to-end suture and nerve grafting with respect to the facial nerve and their superiority to anastomotic operations or to plastic surgical procedures.

BIBLIOGRAPHY.

1. Ballance, C., and Duel, A. B.: Operative Treatment of Facial Palsy by Introduction of Nerve Grafts into Fallopian Canal and by Other Intratemporal Methods. *Trans. Am. Otol. Soc., Inc.*, 21:288-295, 1931. Also: *Arch. Otolaryngol.*, 15:1-70, Jan., 1932.

2. Bunnell, Sterling: Personal communication.

3. Bunnell, Sterling: Surgical Repair of the Facial Nerve. *Arch. Otolaryngol.*, 25:235-259, Mar., 1937.

4. Foerster: Quoted by Stookey, Byron, and Scarff, John: Injuries of Peripheral Nerves. In: *Neurosurgery and Thoracic Surgery. Military Surgical Manuals*, National Research Council, W. B. Saunders Co., Philadelphia, 1943, p. 167.

5. Hoople, G. D., and Johnson, A. C.: Unpublished data.

6. Ney, K. W.: Facial Paralysis and the Surgical Repair of the Facial Nerve. The Laryngoscope, 32:327-347, May, 1922.

GEORGETOWN UNIVERSITY POSTGRADUATE COURSE.

The Georgetown University Medical Center will sponsor an intensive graduate course in oto-rhino laryngology-bronchoscopy by Prof. Georges Portmann, of the University of Bordeaux, France. The course will begin April 7, 1947, and continue for two weeks in Georgetown Medical School, Washington, D. C. Address inquiries to: James A. Flynn, M.D., F.A.C.S., 1511 Rhode Island Avenue, N.W., Washington, D. C.

HISTOPATHOLOGY OF SCLEROMA OF THE UPPER RESPIRATORY TRACT.

ROBERTO MENDIOLA, M.D.,
Guadalajara, Mexico.

Scleroma is an endemic disease of the upper air passages. The bacillus of von Frisch, which lives as a parasite on the tissues, has been considered its pathogenic agent, although it has not been established without question that this is the real causative organism of this disease. In some cases of scleroma the bacillus of von Frisch is found associated with the bacillus of Lowenberg, the coccobacillus of Perez, the bacillus of Avel, the pneumobacillus of Friedlander, staphylococcus pyogenicus and the bacillus lactis aerogenes. In other cases of scleroma all of these organisms may be encountered except the bacillus of von Frisch.

The characteristic lesion of scleroma starts and progresses very slowly. It appears more frequently among the poorest classes. The incidence is highest between 15 and 30 years of age, but it is known that some cases have appeared at as early an age as three years, while others have had their onset in individuals 60 years of age.

The inflammatory lesion usually starts in the nose and secondarily involves the rest of the upper air passages, attacking progressively muscle, cartilage and bone. Characteristic lesions are found most frequently in the anterior part of the nasal cavity. The point of predilection is the upper lip from which it extends upward to the nasal septum, turbinates, cavum, pharynx, larynx, palate and trachea, finally reaching the main bronchi. The extension and intensity of the lesion and the various clinical appearances are related to their duration and to the focal predominance.

Patients usually go on living in good general health for a long time. Scleroma remains with no tendency to ulcerate and

Editor's Note: This ms. received in Laryngoscope Office and accepted for publication, Sept. 11, 1946.

there are neither glands nor lesions in other organs. The disease progresses slowly and, before becoming clinically characteristic, it is preceded by a foul odor and a chronic mucopurulent rhinitis, which may last for months or years. As a consequence of the progressive atrophy of the nasal glands, the mucous membrane appears thickened and covered with green, gray or reddish crusts. Either diffuse, nodular or tubercular infiltrations are to be found in this period, and their size varies from 1 mm. to 2 cm. This infiltrated tissue is characterized by its great hardness. This stage is followed by deformities of the nose and upper lip. Obstruction in different levels of the upper respiratory tract are produced by inflammatory hyperplasia and the intense sclerosis of the healing process. Authors who have observed scleromas in East Prussia, Silesia and the Balkans tell us that it can produce fatal asphyxia by obliterating the trachea and main bronchi. In Mexico, this has not been reported.

Functional disturbances depend upon the regions affected; consequently, nasal obstructions, disturbances in the hearing, dysphagia and dyspnea are more or less accentuated.

INFECTION AND GEOGRAPHICAL DISTRIBUTION.

This disease is well known in the Central American countries, Africa, eastern Europe (East Prussia), Silesia, the south of Russia and the Balkans. In Mexico, the statistics of the General Hospital in 1922 show that in the following regions scleroma is common: Distrito Federal, Guanajato, Michoacan, Morelos, Jalisco, Guerrero, Veracruz, Hidalgo, Queretaro and Oxaca.

The statistics of Dr. Javier Gomez Orozco, in 1936, report cases from Jalisco, Colima, Michoacan, Nayarit and Sinaloa.

HISTOPATHOLOGY.

The initial catarrhal period is not characteristic of scleroma. When the disease is well established, there is a thickening of the nasal mucous membrane and diffuse or nodular changes extend throughout the upper respiratory tract and

into the bronchi. The indurations are very hard and if cut on the plane of section may be observed to have a white-grayish coloring. It is an evasive and progressive process that heals by sclerosis. Affected organs become rigid, and old and new scars may be seen in the same zone. Neither these typical lesions nor the bacillus of von Frisch have been found in any other organ than the upper respiratory tract.

Fig. 1. Scleroma showing complete obstruction of the anterior nares of a 20-year-old woman. Symptoms were of five years' duration.

In the early lesions the inflammatory exudate produces an interstitial edema, slight infiltration of leucocytes, polymorphonuclears, neutrophils and plasmocytes. Macrophages are numerous and diffusely distributed, mixed with other inflammatory cells, and do not show any considerable histological changes, in spite of the fact that they have ingested many of the bacilli of von Frisch. New vessels are scarce. Young fiobroblasts may be observed making the precollagenous (preconnective tissue) material in irregular and unfinished bundles.

The surface of the nasal mucous membrane, because of

progressive metaplasia, is lined by stratified squamous epithelium which is almost always very thick. In some areas it forms a uniform band with the superficial hyalinized stratum. The thick epithelium over the nodules shows a smooth surface, and it is deeply hyperkeratinized by the hyperplasia of the germinal and basal layers. It also forms thick and thin prolongations which anastomose, penetrate deeply into the

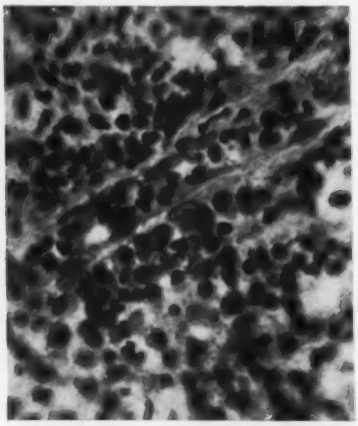

Fig. 2. Initial lesion of scleroma showing the non-specific inflammatory granuloma. New vessels are evident and the inflammatory exudate is characterized by macrophages, polymorphonuclear leucocytes, plasmocytes, lymphocytes and very few young fibroblasts.

underlying connective tissue, and in this way form connective tissue islands. The superficial crusts are made of coagulated fibrinous exudate containing leucocytes, erythrocytes, and debris or masses of keratinized cells. Occasionally the epithelium is destroyed and ulcerated in small localized areas, and the secondary granulation tissue that appears in these regions is covered by coagulated fibrinous exudate which includes numerous leucocytes and debris.

Beneath the epithelium of the early nodules the most characteristic lesion of scleroma can be observed. The inflamma-

tory edema is minimal or absent. A heavy and bulky infiltration is found; the predominance of macrophages and leuco-

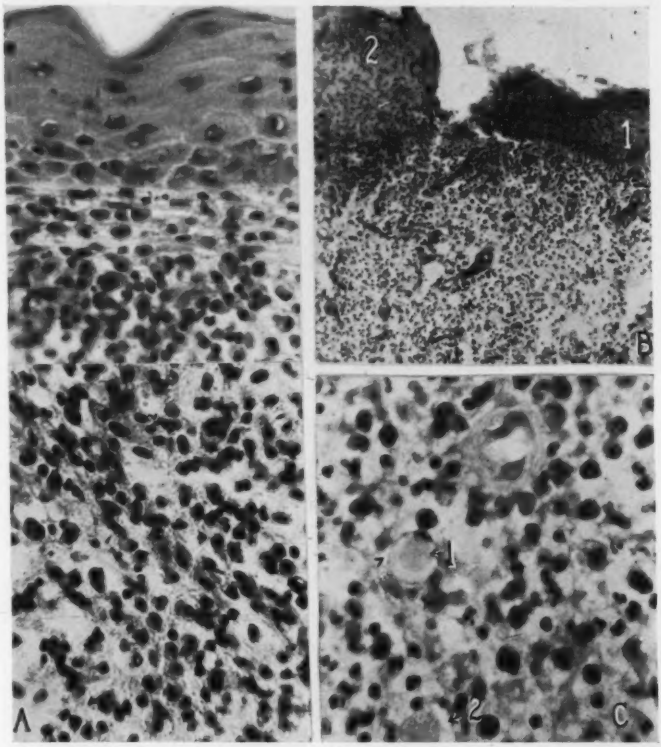

Fig. 3. Nodular type of scleroma. **A.** Tissue from a more advanced lesion in the anterior nares. The stratified squamous epithelium of the mucous membrane is thickened by hyalinization of the superficial layer. Beneath the epithelium the inflammatory infiltration shows numerous unaltered macrophages, plasmocytes, few polymorphonuclear neutrophils and some young fibroblasts.

B. Nodular granuloma of the cavum. (1) Metaplasia with stratified squamous epithelium. (2) Small ulcerated point covered with fibrinous exudate including leucocytes, erythrocytes and detritus. In the rest of the photomicrograph edema, some vessels with hyalinized walls, a great number of macrophages, plasmocytes and lymphocytes can be observed.

C. Same histological section as **B.** The blood vessel in the center shows a thickened hyalinized wall and swollen endothelial cells. (1) Hyaline cell revealing Rusel's bodies and nuclei in a peripheral position. (2) "Foam" cell produced by dropsical degeneration. Many macrophages are present throughout the section.

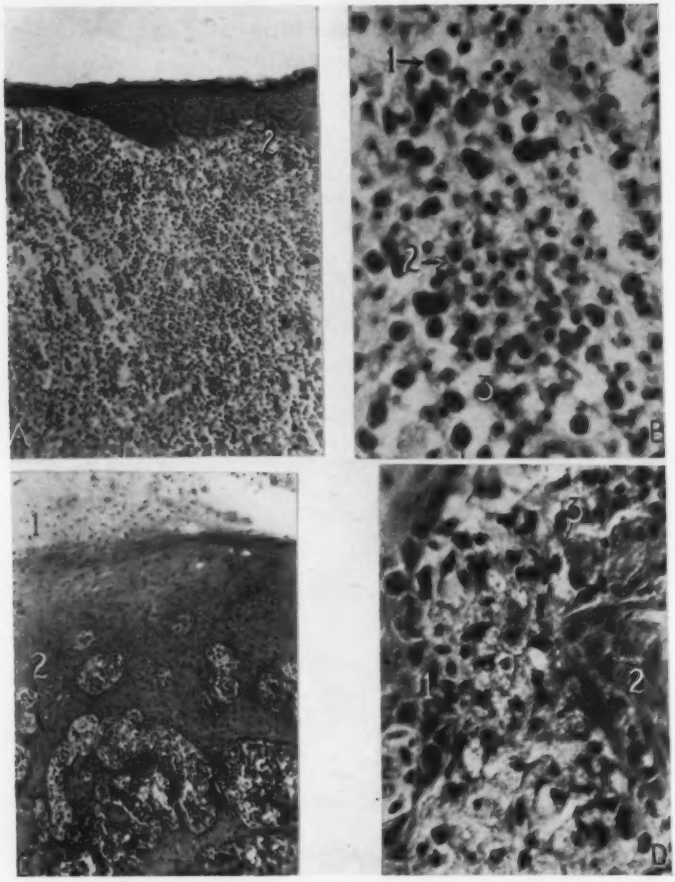

Fig. 4. **A.** Scleromatous nodule in the nasal fossa. (1) Atrophy of the epithelium. (2) Hyperplasia of the stratified squamous epithelium in this area. Inflammatory granuloma showing scarce new growing vessels, some edema, and considerable infiltration with unchanged plasmocytes and lymphocytes.

B. Same histological section. (1) Hyaline cell. (2) Focus of degenerating plasmocytes and lymphocytes. (3) Macrophages.

C. Tubercular nodule of the superior turbinate. (1) Crust. (2) Metaplasia, hyperkeratosis. Epithelial prolongations join each other, enclosing small islands of inflammatory tissue in which may be seen small islands of "foam" cells.

D. Granulomatous island in the same section shown in **C.** (1 and 2) Epithelial borderline limiting the island of inflammatory granuloma. Characteristic lesion of the scleroma. (3) Modified macrophages under the action of the bacillus of von Frisch. They are now forming a dense group of round or polygonal cells whose cytoplasm is clear and reticulated with deformed and stained nuclei. These are Mickulicz's or "foam" cells.

cytes disappears, and plasmocytes and lymphocytes become more and more scarce. Later, only macrophages are seen forming continuous, compact masses. They are especially seen in the islands surrounded by the epithelial prolongations.

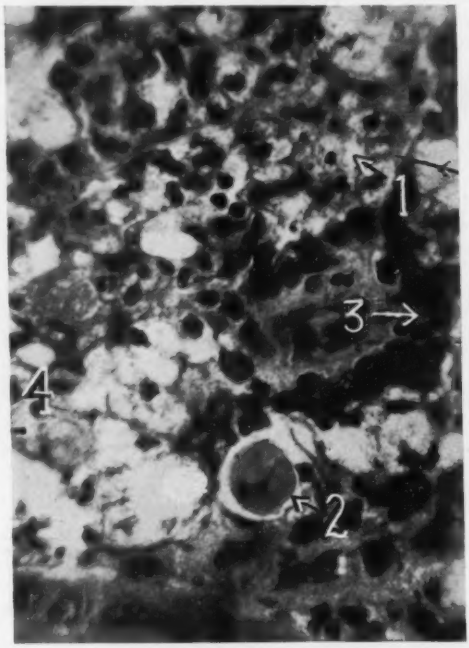

Fig. 5. Nasal nodule. (1) Destruction of plasmocytes and lymphocytes. (2) Great hyaline cell. (3) Hyaline degeneration and obstruction of a vessel. Vessel surrounded by macrophages. (4) Macrophages with dropsical degeneration.

In a more advanced period the normal histology of macrophages diminishes, and those showing morphological and chemical alterations become abundant. These macrophages enlarge in size and assume a round, oval or slightly polygonal shape, due to mutual pressure. Into these dense masses every

histological element is changed and assumes an epithelioid character. The nucleum remains round and retains its staining affinity. The cytoplasm is clear, fine and capriciously reticulated. Filaments of the reticulum are chromatophilic and they circumscribe clear spaces. The total appearance is that of foam or lace, and for this reason they are called "foam cells" or "lace cells."

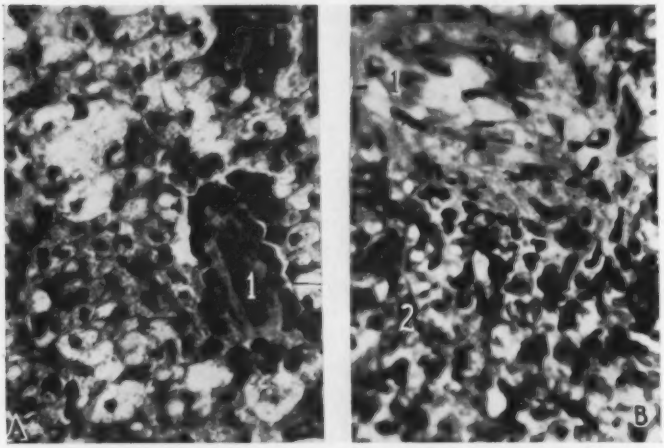

Fig. 6. **A.** Scleroma nodule of the larynx. (1) Swelling of endothelial cells has blocked a vessel. Its walls are thickened and hyalinized. In the adventitia layer a row of macrophages has formed a crown around it. In other places are degenerating macrophages. Leucocytes, plasmocytes and lymphocytes are missing. Some sclerosis is seen in the vicinity.

B. Scleromatous nodule picked from the cavum. Dense scarring has resulted. (1) Sclerotic zone with hyalinization of the collagenous tissue and some fibroblasts. (2) Characteristic island of inflammatory tissue containing "foam" cells, some fibroblasts and a few plasmocytes.

The persistence of the pathologic factor determines the entire hyalinization of the cytoplasm, the reticuli disappear and the cytoplasm is transformed into something larger and completely clear; we can find in it Rusel's granules (or Rusel's bodies or hyaline bodies). The nucleus of the cell is chromatophilic and deformed. Embedded in these cells are groups of bacilli of von Frisch.

Few vessels are encountered in these tissues, and these have thick and hyaline walls. Typical macrophages frequently form a crown on the marginal zone. Endothelial cells become swollen and finally the vascular lumen is obstructed.

In the very old lesions there are no macrophages; they have been substituted by fibroblasts, and an increased amount of the collagenous material is observed, forming bundles in capricious directions. The collagenous tissue becomes hyaline and is almost avascular, but it can include some islands of granulation tissue. Bacilli of von Frisch are found in the neighboring cells and as parasites in the cytoplasm of those macrophages that have ingested them. They continue to live in the macrophages, and because of their action the histiocyte suffers morphological and chemical modifications.

Histiocytes or macrophages of tissues are migrant cells that normally are present in small numbers in all tissues.

It is easy to make a histological diagnosis of this disease in the characteristic granulation period; it is difficult when the granuloma is new or in scarred areas. During these periods we must investigate for the bacilli of von Frisch by taking a biopsy. The biopsy material is ground into a suspension and fixed by heat and alcohol-ether. It is then Gram stained. It is a Gram positive bacillus. Aspiration biopsies are also recommended.

SUMMARY.

1. Scleroma or rhinoscleroma is an endemic and contagious disease which attacks mostly the poor populations. Geographical distribution includes: Eastern Europe, Africa and Central America.

2. The pathogenic agent is the Gram positive bacillus of von Frisch.

3. The following anatomical regions may be involved: nasal fossa, upper lip, cavum, pharynx, palate, larynx, trachea and main bronchi. There are neither lesions nor bacilli of von Frisch in other parts of the body.

4. It is a chronic disease whose evolution takes years. It occurs in adults of both sexes between 15 and 30 years of age.

5. It may terminate fatally by asphyxia or by secondary infection.

6. Clinically and histologically, it is preceded by a protracted mucopurulent rhinitis. A granuloma follows in which we find macrophages mixed with leucocytes, plasmocytes and lymphocytes. Macrophages are predominant and they have no cytological alterations at the onset. Later, we can see a more marked predominance of macrophages.

7. Some morphological alterations occur in the cytoplasm. A chromatophilic reticulum forms many little dropsical spaces. This kind of cell has been called Mikulicz's cell, "foam cell" and "lace cell." They are nothing but modified macrophages containing living bacilli of von Frisch.

8. The granuloma heals by means of sclerotic tissue.

9. Different stages of the development of the lesions are present simultaneously, so that it is possible to observe chronic granuloma, either plain or nodular, and cicatricial lesions in the same region. These pathological changes account for the clinical symptoms of obstruction and rigidity of the air passages.

10. The clinical diagnosis can be confirmed by taking a biopsy to be examined histologically or bacteriologically.

PYRIBENZAMINE IN ALLERGIC RHINITIS (PRELIMINARY REPORT).*†

VICTOR GOODHILL, M.D.,
Los Angeles, Calif.

It is now an accepted dictum that the proper therapy of allergic rhinitis is essentially preventive, *i.e.*, the human allergic organism should be kept alienated from his known allergenic offenders and should be desensitized or hyposensitized to those offenders, especially inhalants, which cannot be practically avoided; however, the acute allergic nasal state and the chronic allergic nasal state require frequent *symptomatic* relief, in spite of our most valiant preventive measures.

It should be noted that this report deals only with the allergic rhinitis problem in Southern California. It deals, therefore, with a type of allergy different from the classical seasonal ragweed hay fever of other parts of the country. Our cases are predominantly perennial in type and non-ragweed in most instances.

The disappointing lack of efficacy of nose drops and nasal sprays in the therapy of allergic rhinitis and the resultant secondary nasal congestion produced by local nasal medication have compelled rhinologists and allergists to seek oral preparations in the symptomatic treatment of allergic rhinitis. Of the oral preparations, the most widely used in recent years have been propadrine hydrochloride and the ephedrine salts (usually combined with barbiturates). Both of these drugs have demonstrated definite advantages over local nasal preparations but have not been uniformly successful in the symptomatic relief of all allergic nasal symptoms, such as sneezing, rhinorrhea, edema and pruritus.

---

*From the Department of Otolaryngology, University of Southern California School of Medicine.

†The pyribenzamine tablets used were supplied by the Ciba Co. See advertisement, page 2.

Editor's Note: This ms. received in Laryngoscope Office and accepted for publication, Aug. 24, 1946.

The Rôle of Histamine and Antihistaminic Substances.

Von Pirquet, in 1908, first described a close connection between anaphylaxis and allergy. Dale and Laidlaw, in 1910, propounded the histamine theory of anaphylaxis. Today, it is quite generally accepted that histamine and allergic reactions are related, and conversely that an antihistaminic substance might conceivably have antiallergic properties.

Since 1937, an intensive search has been made for effective antihistaminic substances. The present report deals with clinical trials of one of the newest of these substances, N'Pyridyl, N'Benzyl Dimethylethylenediamine Hydrochloride (Ciba Compound 63), now known as Pyribenzamine. The mechanism of its action is primarily antihistaminic rather than sympathicomimetic.

Rudolf Mayer and his associates studied a number of alpha-pyridino-ethylene-diamines in relation to antihistaminic activity. They found that pyribenzamine exerted a very potent antihistaminic activity effect by titrating its biological activities on the isolated intestinal strip of the guinea pig subjected to a standard histamine bath. This *in vitro* test was followed by an *in vivo* test in experimental asthma produced in guinea pigs exposed to a histamine aerosol air stream. The production of asthma could be greatly delayed in these animals by preliminary administration of pyribenzamine. Similar protective activity of the drug was demonstrated against the anaphylactic shock produced by horse serum in guinea pigs.

CLINICAL OBSERVATIONS.

Pyribenzamine has been given orally in 50 mgm. tablets to 120 patients with either acute or chronic allergic rhinitis. These patients have all been completely studied rhinologically.

The diagnosis of allergy has been confirmed by a careful history and physical examination; many of these patients have also been studied by cutaneous tests and elimination diets. Where indicated, cytological studies were made.

ILLUSTRATIVE CASE REPORTS.

Case 1: C. N., age 39. Patient was first seen on Jan. 20, 1946, complaining of marked nasal obstruction. Examination revealed almost complete occlusion of the nasal chambers by large edematous polypi. Polypectomy was followed by marked relief and an adequate airway temporarily. Patient continued to complain of profuse watery anterior and posterior rhinorrhea, headaches, sneezing, and itching of the nose, eyes and throat. Pyribenzamine was started by mouth; a 50 mgm. tablet was given three times daily for a week. Within one day he experienced almost immediate relief from all the above symptoms. The only side effect noted was slight sedation if pyribenzamine was taken before meals; there was none if taken after meals. He has remained asymptomatic for the past six months. In past years, he has been very uncomfortable during this particular period of the year. He has since taken the drug only at occasional intervals, in doses never exceeding 50 to 100 mgm. daily. No other treatment has been given during this period.

Case 2: N. L., age 28. Patient was first seen on March 9, 1946. He gave a three-year history of alternating nasal obstruction, rhinorrhea and frequent violent sneezing attacks. There was a strong family history of asthma. Examination revealed a slight septal deflection and a pale, boggy, blue-white nasal mucosa, which reacted very violently with rhinorrhea to attempts at diagnostic shrinkage with ephedrine.

Pyribenzamine therapy in a dosage of 50 mgm. by mouth, morning and night, brought almost complete relief from the sneezing, nasal obstruction and rhinorrhea.

He had been an inveterate user of privine and was a typical example of addiction to that drug. Since starting pyribenzamine he was immediately able to dispense with privine, and requires no drug of any kind, either locally or orally. He takes an occasional tablet of pyribenzamine if he feels an impending attack of allergic rhinitis and is thus apparently enabled to ward off these attacks. He has been very comfortable for four months.

Case 3: L. J., white female, age six. This child has had severe allergic rhinitis for three years. Attempts at specific desensitization by a competent allergist have been unsuccessful. Occasional relief has been obtained from propadrine, but within the past few months none of the oral preparations have helped her. Benadryl made her too sleepy (almost to the point of coma) to be of value. She was seen in June, 1946, and put on pyribenzamine 25 mgm. t. i. d. She has had almost complete relief of her sneezing and nocturnal nasal obstruction without sedation or other demonstrable side effects.

Case 4: Mrs. R. M., age 38. This patient has been observed in several acute exacerbations of chronic perennial allergic rhinitis. Each attack has been somewhat more severe. She has not been cooperative in an allergic investigation. She was seen on July 6, 1946, during another acute allergic attack characterized primarily by marked edema of the inferior turbinates. She did not respond to pyribenzamine in doses of 300 mgm. daily, nor to benadryl in similar doses. Not until actual cautery streaks were made on the edematous inferior turbinates did she obtain relief.

Case 5: B. J., 16-year-old white female. This patient has perennial allergic rhinitis, primarily due to pollenosis; however, she also has severe, well defined food allergies. Chocolate in minute doses produces marked nasal congestion, rhinorrhea and sneezing. Upon ingestion of chocolate 30 minutes following a 50 mgm. oral dose of pyribenzamine, no

nasal symptoms occurred. It was possible to check this effect by several controlled trials. She showed a protective action against chocolate for four to six hours following pyribenzamine administration. We see here an interesting antiallergic effect of the drug in food allergy.

Pyribenzamine has proven a valuable drug in giving symptomatic relief to patients with acute allergic rhinorrhea, obstruction, sneezing and pruritus. One or two 50 mgm. tablets orally have been sufficient in many cases to afford complete relief and apparently end an attack. In other instances, it was necessary for the drug to be repeated every four to six hours to accomplish symptomatic relief. In many patients, rapidity of action was marked, relief occurring within 30 minutes. The excessive rhinorrhea stopped, the airway became wider, sneezing and palatal pruritus and edema ceased or were considerably decreased.

The use of pyribenzamine in five cases of penicillin urticaria afforded prompt dramatic relief. The drug was not given specifically to asthmatic patients, but several of the nasal allergy patients who were also asthmatics reported no relief of their asthma at all while on pyribenzamine.

The most striking effects observed have been in the relief of sneezing and itching. It may be safely stated that no other drug, in the writer's experience, has been of comparable value in relieving the allergic patient of the distressing paroxysms of sneezing and the gnawing misery of itching in the nose, throat or eyes.

Side Reactions: The drug produced only rare dryness in the nose and throat. Central nervous stimulation, rapid pulse and palpitation were conspicuously absent. The latter three phenomena are frequent side effects with oral ephedrine or propadrine administration. Urinary symptoms were likewise absent.

The only undesirable side effects observed with pyribenzamine were only occasional sedation, occasional slight vertigo and rare nausea. It is important to note that sedation with pyribenzamine was infinitely less than that observed in benadryl-treated patients. In only two cases out of 120 was seda-

tion severe enough to make it necessary to stop the medication. With benadryl (another new antihistaminic drug), however, the sedative effect is profound enough to interdict its use in a large percentage of patients.

Conclusions: Inasmuch as this is a preliminary report, no attempt will be made to present full statistical data. It is planned to subject a larger series of patients to future extensive clinical trials with pyribenzamine and other antihistaminic drugs. It is hoped that other workers in this field will be stimulated to study these new antihistaminic drugs in allergic nasal conditions.

The effectiveness of the drug in relief of itching and sneezing was approximately 90 per cent; however, the drug was only about 70 per cent effective in the relief of nasal congestion and rhinorrhea.

It was also observed that pyribenzamine given orally diminished skin reactivity to pollen extracts in patients previously markedly skin sensitive.

It is of interest to observe clinically that the pharmacologic activity of pyribenzamine is apparently antiallergic rather than sympathicomimetic. The ephedrine and propadrine preparations are sympathicomimetic and in this fashion have antiallergic qualities; but they will reduce nasal congestion in infectious rhinitis and sinusitis as well as in allergy. Pyribenzamine, however, seems to have very little sympathicomimetic activity in that it demonstrated very little nasal decongestive effect in infections. It was primarily effective in nasal edema of allergic origin.

The true rôle of histamine in the allergic state is still unsettled. The release of histamine-like substances in infections has also been under scrutiny; however, at the present state of our knowledge it is safe to say that histamine release and histamine action is more probably characteristic of allergy than of infections. (For the purposes of this preliminary report, the controversial subject of bacterial allergic phenomena will be omitted.)

We can thus see that in the human, the original animal experiments seem to be borne out, proving the essential antihistaminic; *i.e.*, antiallergic effect of this new drug.

SUMMARY.

A preliminary report is presented detailing experiences in the symptomatic treatment of allergic rhinitis orally with pyribenzamine, a new antihistaminic drug. It has been found to be an especially valuable drug for the relief of sneezing and itching of the nose and throat, as well as an efficient nasal decongestant in nasal allergy.

BIBLIOGRAPHY.

1. Von Pirquet: Allergie, J. Springer, Berlin, 1908.

2. Dale, H. H., and Laidlaw, P. P.: The Physiological Activity of Beta-iminoazotylethylamine. *Jour. Physiol.*, 41:318, 1910.

3. Mayer, Rudolf: Antihistaminic Substances with Special Reference to Pyribenzamine. *Jour. Allergy*, 17:3:153-165, May, 1946.

4. Mayer, R. L.; Huttrer, C. P., and Scholz, C. R.: Antihistaminic and Antianaphylactic Activity of Some Alpha-pyridino-ethylene Diamines. No. 2639 *Science*, July 27, 1945, Vol. 102.

676 South Westlake.

THE PRESENT STATUS OF OTOLARYNGOLOGY IN THE UNITED STATES ARMY.*

NORTON CANFIELD, M.D.,
New Haven, Conn.

Medical specialty practice in the United States Army has been accepted and forms an integral part of the Army's *planning* for the care of the sick and wounded. Specialty service to the soldier in both of the recent wars has been responsible for medical progress in several important fields. Outstanding physicians have seized upon conditions found only during the war to study and determine the benefits and dangers of new methods and techniques. Neurosurgery had its great impetus during the first World War; preventive medicine probably shines as the bright star of progress in World War II. During World War I, otolaryngology was high in its orbit of influence and the Armed Service authorities in Washington saw fit to provide a special course to train men in otolaryngology to assume specialty assignments in the Army. In the years 1935-1940, otolaryngology stood a bit eclipsed by the advent of chemotherapy, the general lack of basic scientific work in the specialty, and the general improvement in the control of infectious diseases which so often found access to the body through the cavities of the head. With the advent of World War II, the Surgeon General's office was charged with the responsibility of providing the medical service for the Army, including a tremendous Air Force. Aviation medicine was so important that a special Air Surgeon's office managed its problems. Research projects were started, new diseases emerged, and the medical care of the flyer became a prominent specialty.

A review of the otolaryngologic manpower of the country, at the outbreak of war, seemed to indicate enough specialists to service both the Army and the civilians. Consequently, no

*Read at the Seventy-eighth Annual Meeting of the American Otological Society, Inc., Chicago, Ill., June 1, 1946.

Editor's Note: This ms. received in Laryngoscope Office and accepted for publication, July 23, 1946.

special training programs were started. Recommendations by civilian otolaryngologists regarding induction examinations including testing of hearing and use of specialty ability were not approved by the Surgeon General. The professional advisor group in Washington on duty at the Surgeon General's office did not include an otolaryngologist. The General Surgery Branch was given responsibility for this specialty and guided it through the war until July, 1944, when an otolaryngologist was appointed to the Surgeon General's office. This officer's chief duty was to coordinate the three Aural Rehabilitation Centers which had been established during the early months of 1943. He came to the Surgeon General's office as a major and was not promoted during his duty in Washington. He was consulted on matters of general otolaryngology, but the specialty was dominated in the Surgeon General's office by the Chief Consultant in General Surgery. This policy of the Surgeon General was reflected in the specialty practice in the U. S. A. and in foreign theaters of war, in that there was in no high eschelon of the Medical Corps an officer whose chief professional interest was otolaryngology except in the European theater.

The essential organization of the Army must be understood. Headed by the Secretary of War, it consisted of the General Staff under which there were three main divisions, the Ground Force, the Air Force and the Service Forces. The Ground Force and the Air Force had medical personnel attached to accompany them into battle, but most of the medical work of the Army was done by the men in the Medical Corps working under the command of the Service Forces. The Medical Corps, then, was not independent and could implement policies of importance only with the consent and approval of the Service Forces Chiefs. The Service Forces limited the number of men, the rank and the duties of medical officers and enlisted men and hence could and did exercise direct influence on policies of benefit to the sick and wounded. Recent reorganization of the Army may change this line of command, but this remains to be seen.

War medicine involves many more sick than wounded, and

hence much of the specialty practice is similar to civilian medicine. Only when the battle is on is there a great difference in the type and number of casualties, and at this time the attention of the medical authorities must be directed toward the battle casualties. It was obvious that after the battle started several specialties were to be in great demand for additional personnel. The numbers of plastic and neurosurgeons had been increased by special training courses. Otolaryngology was not so augmented, although there were sporadic attempts to train younger men in a few instances. In the European theater, where we had more than 100 General 1,000-bed hospitals, facilities for training were very possible and were recommended. This could only be accomplished in three of 30 possible hospitals for two reasons:. *First,* there were no extra medical officers to train as each unit was so very limited by its organizational setup; *second,* it was expected that all hospitals sent over would have at least one well trained otolaryngologist. The domestic supply of otolaryngologists, however, ran out, so that in late 1944 and early 1945, 30 General Hospital units arrived with no otolaryngologic personnel. Each of these units was a 1,000-bed General Hospital. It was necessary to have one man cover two or more hospitals and send patients from one hospital to another. This was not difficult as long as the hospital concentration was heavy as in England, but in France it was not as satisfactory. Proper policies established and executed within the Medical Corps could have greatly facilitated those arrangements but they so frequently involved Service Force channels of command that inferior service to the men who needed the care was a frequent result.

The type of otolaryngologic service needed by the Army is special in some respects. Induction examinations are important and in one respect were extremely inadequate. This involved the ears, both from the standpoint of infection and hearing. The chronic suppurating ear is a detriment because of the time off duty for so many men. The deafened ear is a detriment because it is an important physical handicap jeopardizing the man himself and his fellow-soldiers. Fortunately, however, when the Army realized how many deafened

soldiers were on duty, they initiated and operated a system of rehabilitation which now stands as a model for the entire profession and should be simulated in civil life for all the deafened citizens of the country.

Most otolaryngology in the Army is of a routine and easy type. Volume is heavy, but difficult cases occur infrequently except during the battle, when other specialists, who have been waiting during most of the non-fighting periods, are ready to start. The plastic and traumatic surgeons, who up until then had little to do, came to the fore. The dentists took on added interest in fractured jaws, upper and lower. The otolaryngologist continued with his usual routine, and although willing and able to assume added responsibility with the traumatic cases, often found he had little time for them or that the cases were handled without the benefit of his experience with the nose and sinuses. Where traumatic head teams could be organized, however, the otolaryngologist frequently occupied his rightful rôle and did his most important traumatic work.

What are the accomplishments to which otolaryngology can point as its professional contributions during the war? Aerootitis media has been the subject of much effort. Investigations have explored the extent of the problem and its effect on the individual flyer. The radiation treatment of nasopharyngeal and Eustachian tube lymphoid tissue has been under the direction of Crowe and Fowler, reports from whom have been published.[1,2] It has added an important therapeutic and preventive tool to our previous methods, and analysis of the results indicates that the method has significant merit. An important corollary to this work has been the collection of 150 pairs of temporal bones for microscopic study, chiefly through the efforts of Fowler during his Army duty in England.[3]

Deafness from warfare has been studied and several series of cases are reported showing audiometric losses, many of which were not known to the patient because the frequencies above 2,048 were often the only ones affected. Reports from Hoople, Friedman and Hipskind[4,5,6] draw attention to this

group of cases. The study of tympanic membrane trauma has again revealed the regenerative powers of this structure in the absence of infection.

For the prevention of acoustic trauma, the Army's answer of soft earplugs came too late to have proper field trials,[7] but in various active units a combination of effort by the otologist and dental technicians produced some very acceptable ear protectors. In one group of mortar battalion personnel, this reduced the number of casualties from about 3 per cent to 0. Other studies presented a more rapid method of treating Vincent's infection of the tonsil.[8] The chief ear disease in the Pacific area was external otitis due to several organisms. Response to treatment varied with different observers with no particular method emerging as the procedure of choice. No single drug was determined to be specific for the condition, probably because of varying etiology.[9]

War wounds of two types received special attention. One type was very well presented in the volume sponsored by the National Research Council. This was the facial wounds where sinuses and the nasal cavity were extensively involved. Kazanjian mentioned many of the important points for proper handling, but the high velocity bullet caused damage to an extent that was not indicated by its size.[10] The explosive effect of a solid object passing at high speed through tissue caused necrosis beyond the confines of the bullet tunnel with tissue seriously injured within the range of the explosive effect. Insignificant external wounds, then, might be accompanied by severe deep injury especially if the missile did not remain within the body. If it was not going rapidly enough to penetrate the entire head, it caused far less damage unless it actually lodged in an unfortunate place, such as the mastoid, a sinus cavity, the temporomandibular joint region, or so that it interfered with some important function.

The second type of war wounds which received special attention were the injuries to the facial nerve from direct trauma. So satisfactory is the result from anastomosis of the two ends of this nerve and homogenous grafts between the central peripheral ends that Lathrop, Hoople and Johnson

demonstrated the feasibility of their procedures in severe wounds of the region. Their contribution has been the fact that in most cases both ends could be *found and joined* even though the lacerations were extensive. One report has been published, others are being prepared.[11]

Decrease in auditory acuity has been a very special interest in the Army and it has been the good fortune of a few otolaryngologists to be intimately involved in this program. Special tribute is due the late Walter Hughson for his inspiration and guidance in this entire program. Three centers for deafened Service personnel were established and have processed approximately 10,000 whose hearing was depressed either before entering or during Army duty. The Navy has a similar program through which have gone 3,000 more. The program was visualized as one of complete rehabilitation beyond improvement of the actual hearing itself. About 40 per cent of the 10,000 cases came into the Army with hearing defects requiring special attention, the other 6,000 were those whose hearing was made less acute by Army duty. Surprising progress can be made in a short four to eight weeks' course during which concentration from several viewpoints is centered on the deafened person. Careful testing to determine the actual hearing level, screening to select the psychological cases, selection of and practice with hearing aids, auditory training, psychological aid, if necessary, psychiatric evaluation, speech correction and lipreading instruction, all entered into the course. The central goal to be obtained was to overcome the handicap by training and to provide acoustic assistance with hearing aids. Gathered together at each center were the otologists, psychiatrists, psychologists, physicists and audiometricians, speech correctionists and lipreading teachers, plus a technical staff for recording and keeping the apparatus in working order. The three centers are now winding up their efforts with a statistical analysis which should produce answers to many questions based on enough cases to be accurate for predicting future phases of the whole program.[12] Late reports of these cases are now being prepared. The Chief Medical Director of the Veterans Administration is enough impressed with the results so that he has authorized much the same pro-

gram for Service connected cases that are beneficiaries under existing Veterans laws. The Veterans Administration now recognizes audiology as a medical specialty and has accorded it the same authority and opportunities as any other surgical or medical specialty.

The postwar Army is in an unsettled state, so definite plans for specialty medical service are nebulous. Of 115 civilian doctors who have recently been accepted for commissions in the regular Army, none are listed as being otolaryngologic specialists. One is listed as a combined ophthalmologist and otolaryngologist. He has not been certified by either board. The regular Army has 12 qualified otolaryngologists, all of whom during the war were in executive positions not requiring their special training for actual care of patients. Of these 12, seven have been certified by the American Board of Otolaryngology. Training has been discussed and some planning is being done. There is need and opportunity for superior otolaryngologic service within the Army, but it seems at present that the national medical manpower shortage will affect the Army more than other groups that are organizing medicine. Politics, as we know it in this country, remains a dominant force in all manner of human effort. If we, as specialists, want to increase the value of our service, it behooves us to give support to any of our group whose urge is to know and make known the political angles which are rapidly developing. We should maintain direct contact with governmental agencies which are now making gigantic efforts to administer the facilities providing medical service in this country. Unless the organized groups of practitioners remain in contact they will be impotent in their influence to mold the policies and will be the victims of more energetic and domineering members of the profession. The present status of otolaryngology in the Army is an example of our lack of this direct contact with authorities in the Army during the war. The time now is propitious to lay the groundwork for improving the heritage which we are to leave for our successors. This can only be done by active initiative on the part of the societies which represent the best specialty practice available in our country today. The demands of the Veterans Adminis-

tration are beginning to be felt. Pressure will come for us to be of service. My belief is that the specialty can be prepared in the same manner as the agencies requesting our help are prepared. We must be represented at the highest administrative levels, so that we can have some voice in the essential policy making which is so important to the welfare of those patients who can best benefit by our professional efforts.

REFERENCES.

1. Fowler, E. P., Jr.: Use of Radon to Prevent Otitis Media Due to Hyperplasia of Lymphoid Tissue and Barotrauma. *Arch. Otol.*, 40:402-405, Nov., 1944.

2. Fowler, E. P., Jr.: Irradiation of the Eustachian Tube. *Arch. Otol.*, 43:1-11, Jan., 1946.

3. Fowler, E. P., Jr.: Personal communication.

4. Hoople, Gordon: Battle Noise Trauma. Presented at the meeting of the American Otologic Society, Inc., May, 1946 (in press.)

5. Friedman, Oral: Personal communication (in press).

6. Hipskind, Myron: Personal communication (in press).

7. O. S. R. D. reports in the Surgeon General's Office, Washington, D. C.

8. Hoople, Gordon: Vincent's Infection of the Tonsils. Presented at the meeting of the Section of Laryngology of the Royal Society of Medicine, London, April, 1945.

9. *a.* Senturia, Ben H.: Etiology of External Otitis. The Laryngoscope, 55:277-293, June, 1945.

b. Nelson, Roy S.: External Otitis in South Pacific. *Ann. Otol., Rhinol. and Laryngol.*, 54:367-372, June, 1945.

c. Quayle, A. F.: Otitis External in New Guinea. *Med. Jour. Australia*, 2:228-231, Sept. 2, 1944.

d. Senturia, Ben H., and Wolf, Ford T.: Treatment of External Otitis: Action of Sulfonamides and Fungi Isolated from Cases of Otomycosis. *Arch. Otol.*, 41:56-63, Jan., 1945.

10. Kazanjian, V. H.: Repair of Facial Wounds. *War Ophthal. and Otol.* Published under the direction of the National Research Council, 1942.

11. Lathrop, Frank: Facial Paralysis Due to War Wounds. Presented at the meeting of the American Otological Society, Inc., May, 1946 (in press).

12. Statistical analysis of Aural Rehabilitation Centers in the Army being prepared by the Surgeon General's office.



Central Institute for the Deaf

NATIONAL RESIDENTIAL AND DAY SCHOOL FOR THE DEAF AND DEFECTIVES IN SPEECH

Approved by Advisory Council of Foremost Ear Specialists and Educators

New fire-proof buildings beautifully located opposite Forest Park. Modern Dormitories and Equipment. Best home environments. Pupils constantly in care of teachers or experienced supervisors.

ORAL SCHOOL FOR DEAF CHILDREN

C. I. D. offers all advantages of exclusively Speech Training and expert medical supervision for both Resident and Day Pupils.
Nursery School (2 years of age) through the Elementary Grades.

ACOUSTIC TRAINING FOR CHILDREN WITH RESIDUAL HEARING

Salvaging of Residual Hearing is a specialty of C. I. D. The Acoustic Method was created here. Group and individual hearing aids used for class instruction at all grade levels.

LIP-READING INSTRUCTION

Private and Class Instruction for Hard-of-Hearing Adults and Children.
Conversational Classes for advanced pupils. Speech conservation stressed.

CORRECTION OF SPEECH DEFECTS

Private and Class Instruction for children with normal hearing and delayed speech or defective speech.
Resident and Day Pupils (2 years of age through Elementary Grades).
Private Instruction for Adults.
Correction of Imperfect Phonation, Imperfect Articulation, Aphasia, Stuttering.

TEACHERS TRAINING COLLEGE

Two years of Training following a professional curriculum for applicants with adequate college qualifications. Graduates qualify for degrees of Bachelor of Science in Education or Master of Science in Education from Washington University. Graduates prepared to teach both the deaf and speech defective.

DR. MAX A. GOLDSTEIN, Founder · MISS JULIA M. CONNERY, Principal Emeritus

For further information address

DR. HELEN SCHICK LANE, Principal

818 S. KINGSHIGHWAY 10, ST. LOUIS, MO.

CONTENTS

My Milestones. Harris P. Mosher, M.D., Marblehead, Mass. - - 639

Peripheral Facial Paralysis. Some Aspects of Its Pathology. Terence Cawthorne, M.D., London, England - - - - - - - - 653

Facial Nerve Surgery in the European Theater of Operations. Frank D. Lathrop, M.D., Boston, Mass. - - - - - - - - - - 665

Histopathology of Scleroma of the Upper Respiratory Tract. Roberto Mendiola, M.D., Guadalajara, Mexico - - - - - - - - 677

Pyribenzamine in Allergic Rhinitis (Preliminary Report). Victor Goodhill, M.D., Los Angeles, Calif. - - - - - - - - - 687

The Present Status of Otolaryngology in the United States Army. Norton Canfield, M.D., New Haven, Conn. - - - - - - 693